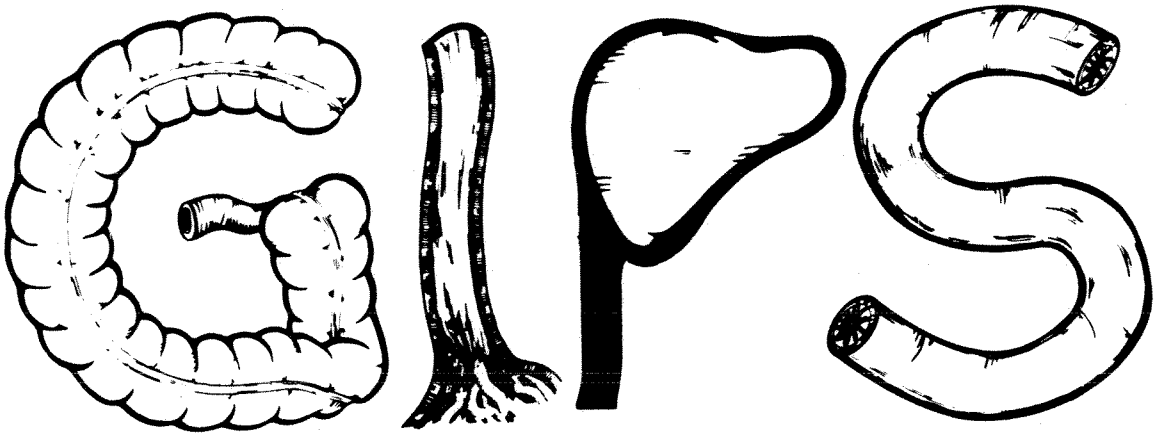

THE GASTROINTESTINAL PATHOLOGY SOCIETY
NEWSLETTER

VOLUME 9, NUMBER 1
Winter, 1991

CONTENTS

Message from the President 1
Editorial
David F. Keren, M.D. 2
Symposium Review
XVIII International Congress of The International Academy of Pathology
David Owen, M.B. 3
Letter to the Editor
Logo Suggestions
Ermes Garnica A., M.D. 6
Secretory IgA and Gastrointestinal Pathology
David F. Keren, M.D. 9
Colorectal Neoplasia
March 17, 1991 16
Book Reviews--
Diagnostic Pathology of the Intestinal Mucosa: An Atlas and Review of Biopsy Interpretation 26
Reviewed by: A. Brian West, M.B.
Transabdominal Fine-Needle Aspiration Biopsy 27
Reviewed by: Linda D. Ferrell, M.D.

MESSAGE FROM THE PRESIDENT

As well as having a major interest in the practice of G.I. pathology, I am also involved in postgraduate training, particularly at the residency and fellowship levels. It has recently become apparent to me that across Canada and probably the whole of North America there is presently a general disinterest among pathology trainees in persuing any sort of an academic career. This applies not only to basic research areas, but also extends to clinical sub-specialization, including G.I. pathology. For example, a fellowship program in G.I. pathology has recently been established at our University. It is fully funded (indeed generously funded), there is a wealth of biopsy material and no scut work, and a variety of interesting projects are ongoing. Positions are readily available at Canadian Universities for our program graduates. Despite this we have been underwhelmed by the number and calibre of applicants. This is occurring at a time when our community pathologists are constantly inquiring about the availability of 1-2 week refresher courses which will enable them to become their hospitals G.I. expert! This situation appears to be not unique either to our area of the continent or to G.I. pathology. I am concerned that training programs are not producing enough young G.I. pathologists to fill the shoes of those that retire, let alone satisfy increased demand. The end results of this will be that Gastroenterologists become increasingly dissatisfied with the lack of subspecialist diagnosis and attempt to do the job themselves.

For these reasons I regard the work of the Training Programs Committee as a crucial area of GIPS activities. They have already done an excellent job in collecting and disseminating information about training programs. Now, I think we need some means of actively encouraging and promoting G.I. pathology as a worthwhile career. Our target should be pathology residents. Suggestions from you, the membership as to how this may be achieved would be valuable. I have some ideas, but please call me with yours.

David A. Owen, M.B.
Vancouver, B.C.

Editorial

It has been my pleasure to serve as Editor of the GIPS Newsletter for the past three years. This job consists mainly of gathering information from the members of GIPS and attempting to present it in a manner which, upon arrival, will an avoid instant designation as *circular file material.* I was fortunate to recruit several of our members to write review articles and guest editorials about their areas of interest. This is my opportunity to thank the many authors who have contributed to these efforts over the past three years. I owe a great debt to our president David Owen for his tireless efforts to encourage members to write reviews of relevant texts for our members.

The GIPS Newsletter is unique in providing a friendly, yet authoritative place for discussion of issues related to our discipline. In this issue, you have the opportunity to review several newly proposed logos for our Society, a preview of the upcoming USCAP GIPS scientific session, a review on mucosal immunology related to the gastrointestinal tract and two timely book reviews. Therefore, I encourage you to keep the GIPS Newsletter relevant to your interests by sending the new editor, Harry Cooper, your ideas, concerns, opinions, poems, etc. related to gastrointestinal pathology.

See you at the meetings--David F. Keren (X-editor)

Report of GI Pathology Activities at the
XVIII International Congress of The International Academy of Pathology
Buenos Aires, Argentina, September 1990

I attended this meeting and thoroughly enjoyed all aspects of it. Socially, there was a varied and interesting program characterized gastronomically by the consumption of inordinately large and delicious steaks along with excellent red wine in quantities that I believe are considered by some to be injurious to the liver.

Scientifically one of the highlights was a symposium on premalignant conditions of the gastrointestinal tract which was organized by Juan Lechago. This included contributions from Dr. F. Potet (France) on Barrett's metaplasia and adenocarcinoma of the esophagus, Dr. T. Hirota (Japan) on chronic gastritis intestinal metaplasia and gastric adenocarcinoma, Dr. Y. Dayal on pernicious anemia, gastric atrophy and gastric carcinoids, Dr. Bob Pascal on lymphoproliferative disorders and lymphomas of the digestive tract, and Dr. Fenoglio-Preiser on inflammatory bowel disease, dysplasia and colonic malignancy. This symposium was extremely well attended and was clearly a big success. Unfortunately, scheduled for the same time was another symposium on the geographic pathology of gastric carcinoma. I would have been interested in this also, but alas I could not be in two places at the same time.

The liver pathology was highlighted by a slide symposium organized by Dr. Ken Barwick. This included cases presented by Drs. Barwick, Porta, Paronetto, and Chedid from the U.S.A. as well as Dr. French from Canada and Dr. Opolon from France.

The program of oral presentations was a little disappointing in that some interesting papers were not given because the speaker did not show up! In addition some presentations were given in Spanish, without translation. I can read Spanish quite well and speak it in hotels and restaurants, but this was a little too much for me. Nevertheless, I did enjoy the following contributions.

From Emory University in Atlanta - Drs. Pascal, Simonetti, McGarity, and Amerson presented "Evaluation of Two Additional Histologic Parameters in the Differential Diagnosis of Inflammatory Bowel Disease". These authors examined 48 resection specimens of colon performed for IBD (UC-27 cases, CD-13 cases and indeterminate colitis - 8 cases). The two histologic parameters evaluated were a) focal superficial inflammation of the muscularis propria with myocytolysis (SIMP) and b) perivascular inflammation of perforating vessels without myocytoloysis. They found that all cases diagnosed as IC at the time of colectomy had focal SIMP and that 5 of these patients (71%) subsequently developed features of CD. Seven of the cases initially classified as UC showed areas of SIMP and two of these (33%) subsequently developed clinical evidence of CD. The authors concluded that the presence of SIMP is highly suspicious for CD and its presence should probably preclude patients receiving a subsequent ileoanal anastomosis. In contrast, inflammation tracking along vessels in the bowel wall irrespective of the depth was seen in all types of IBD and was not considered a useful point of differential diagnosis.

From the University of Ottawa in Canada, Drs. Idus, Wenckebach, Soucy, and Keeley presented a detailed description of the pathology of spontaneous rupture of sigmoid colon in Ehlers-Danlos syndrome type IV. Significant, previously unreported features included white plaques covering the serosal aspect of the colon which consisted histologically of areas of fibrosis and elastosis. There was an accumation of ground substance and disruption of the elastica in small blood vessels. Perforation appears to be due to deficient and altered collagen fibers within the muscularis propria which offer inadequate support against an increased intralumenal pressure.

Predicting relapse in ulcerative colitis: The role of rectal biopsy was the topic of a presentation by Drs. Riley, Dutt, and Herd from Hope Hospital and Salford and Bury General Hospital in Manchester, England. These investigators examined rectal biopsies from 82 patients with ulcerative colitis in clinical and sigmoidoscopic remission. During a 12 month follow 33% of patients relapsed with the relapse rates being unrelated to disease duration, disease extent or current drug therapy. Findings in the rectal biopsies that did correlate with later relapse included: 1. Acute inflammatory cells infiltrate in lamina propria. 2. Crypt abscesses. 3. Mucin depletion. 4. Superficial ulceration. The investigators felt that these were histologic features that had a high interobserver agreement.

Drs. Owen and Wolber from Vancouver, Canada presented a paper on flat adenomas of the colon. Modesty prevents me commenting further on this excellent contribution.

From the Rambam Medical Center and the Technion Faculty of Medicine in Haifa, Israel, Drs. Lachter, Lichtig, and Munichor presented a paper entitled "Mast Cells in Colorectal Cancer and related disorders". In order to evaluate mast cell function involving basement membrane and collagen layer thickening, the authors counted mast cells and measured basement membrane thickness in a number of colonic neoplasms and non-neoplastic polyps. They found there was no association between the number of mast cells present and the thickness of the basement membrane. However, mast cells were significantly more frequent in adenocarcinomas than they were in normal controls. Mast cells in colonic adenomas were present in intermediate numbers.

From the University of the Orange Free State in South Africa, Drs. Middlecote and Van Wyk, Bester, and Van Zyl presented an endoscopic and autopsy study on lipofuschinosis and hemosiderosis in the black population. These authors studied 47 gastric antral biopsies where fragments of muscularis mucosae were present. In 14 of these lipofuschinosis was noted. The median serum ferritin level in this group was 1157 micromol/L. In the lipofuschin negative group the median ferritin level was 248. Furthermore in 20 of 108 autopsy cases where lipofuschinosis was present, 19 showed moderate to severe hemosiderosis. Lipofuschinosis was not noted in any autopsies of whites. The authors postulate that lipofuschin results from oxydation of polyunsaturated lipids due to an excess of iron (a pro-oxidant) and a deficiency of vitamin C

(an antioxidant) secondary to iron overload and that there is a relationship between these two conditions.

From the Hospital de Clinicas in Buenos Aires Drs. Avagnina, Perez, Elsner, Tano, and Fay presented their study of histological and immunohistochemical findings in patients with chronic hepatitis B who were treated with recombinant alpha interferon. 38 patients were studied. 21 seroconverted from HBe Antigen positive to anti HBe and from HBV - DNA positive to negative. 17 did not seroconvert. The authors observed a significant decrease in the severity of inflammation in the seroconverted group. However, the degree of fibrosis was similar in the seroconverters and the non-seroconverters. The authors conclude that seroconversion whether it is spontaneous or induced by interferon reduces liver inflammation significantly and stops viral replication.

Some interesting posters were on display also. A study by Dr. Adad from Minas Gerais in Brazil demonstrated the changes in 56 cases of Chagas disease of the esophagus. 17 of these patients had a mega esophagus which was considered to occur when the diameter of the esophagus was greater than 2.5 cm. Loss of ganglion cells from the myenteric plexus was more severe in the cases of mega esophagus confirming that the diltation is the result of denervation.

From the Instituto Oswaldo Cruz in Rio, Dr. Vidal Schaffer presented a case of gastric syphilis. As pointed out by the author this was remarkably similar grossly and microscopically to linitis plastica. Microscopically marked submucosal fibrosis was present with foci of endarteritis and periphlebitis.

A poster by Drs. Yamabe, Shima, Kobiashi, and Ichijima (Kyoto and Nara), Japan described their 20 year experience of primary gastric and primary intestinal lymphomas. They found a similar sex ratio, age of presentation and symptomatology. However, intestinal lymphomas tended to be larger and invade more deeply than gastric lymphomas. Furthermore, more high grade lymphomas were present in the small bowel. The five year survival for gastric lymphomas was 58% and for intestinal lymphomas only 8%.

I also enjoyed a poster from Sapporo, Japan by Dr. Kikuchi, Ishikura, Sato, Takahashi, and Kikuchi which beautifully demonstrated the pathology of gastrointestinal anisakiasis. These lesions are found mainly in the terminal ileum and are characterized by bowel wall thickening with surface erosions mimicking malignancy. Histologically, the picture may range from dense eosinophil infiltration through neutrophil infiltration to granuloma formation with fibrosis. After seeing this poster I was careful to order my steak dinner well done!!

David A. Owen, M.B.

Dr. Ermes Garnica A.
Hospital Oncológico Padre Machado
Department of Gastroenterology

Caracas, November 24, 1990

David F. Keren, M.D.
2008 Hogback Road
Ann Arbor, Michigan 48105
U.S.A.

Dear Dr. Keren,

Along those eight volumes, the GIPS Newsletter have becoming in a every time more interesting periodicals. The reviews of books and abstracts are very selected and accurate as well as the conference notes.

I have studying the first page format and my conclusion is that the LOGO of GIPS is not appropriate. It is, in deed, very "expressive" but, from an artistical point of view, it is a little less than "fatal".

I think we all have the duty to collaborate in any way with our Society, then, I decide to draw some ideas about the GIPS' logo and submit them to you to know your opinion and, in the case you decide that any of the sketches is appropriate, please feel free to take any of them and send it back to me or to any other who can make the final art with the modifications or suggestions you may have.

Enclosed you will find several sketches with the proposed GIPS' logo.

Sincerelly yours,

Ermes Garnica A., M.D.

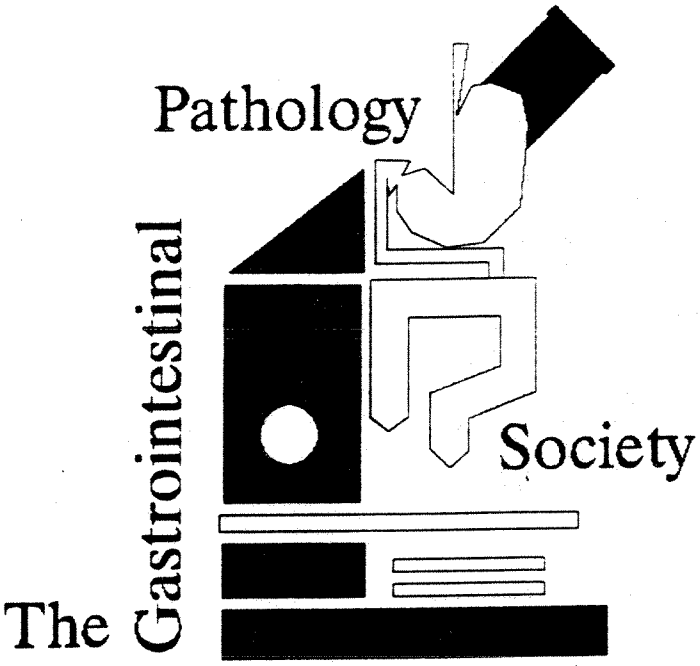
Pathology
The Gastrointestinal
Society

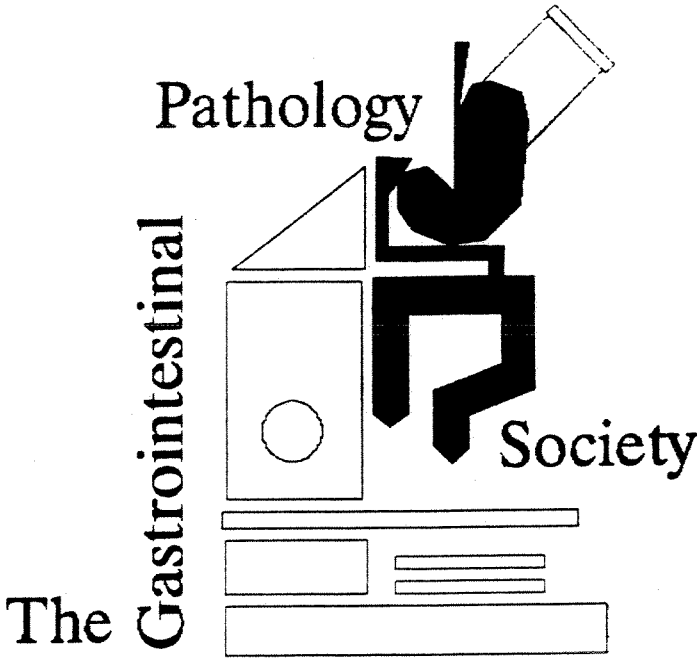
Pathology
The Gastrointestinal
Society


Pathology
The Gastrointestinal
Society


Pathology
The Gastrointestinal
Society


The
Gastrointestinal
Pathology
Society


The
Gastrointestinal
Pathology
Society

Secretory IgA and Gastrointestinal Pathology

David F. Keren, M.D.

As we ponder biopsies from our favorite sites along the gastrointestinal tract, we always must consider the chronic inflammatory cell content. The plasma cells and lymphocytes are of interest in patients with many conditions, often pointing toward the appropriate diagnosis: common variable immunodeficiency syndrome, atrophic gastritis, Mediterranian lymphoma, ulcerative colitis, Crohn's disease and acute self-limited colitis. For instance, the number of plasma cells in the lamina propria is one of the useful features which helps us to distinguish patients with active idiopathic inflammatory bowel disease (IBD) (with marked increases in plasma cells) from those with acute self-limited colitis (where normal numbers of plasma cells are found).

The vast majority of the plasma cells in the intestine synthesize and secrete IgA. Secretory IgA (the main specific immune defense mechanism for mucosal immunity) was first described in 1959, yet not until 1965 was it demonstrated to occur mainly on mucosal surfaces. While much experimental evidence has been gathered in the ensuing twenty-five years, we still lack many important details of how to best stimulate the mucosal immune response to many relevant enteropathogens and their toxic products. The presence of a mucosal immune system in lower vertebrates implies that mucosal immunity confers a significant survival advantage in a variety of environments. Indeed, gut-associated lymphoid tissue (GALT) has been detected in agnathans, elasmobranchs, amphibia, and reptiles (1).

The humoral immune response along mucosal surfaces differs markedly from that in the serum. While administration of an antigen systemically evokes a strong IgG response with little IgA in serum, mucosal surfaces elaborate secretory IgA as their main response to stimulation by antigens applied to the mucosal surface. Interestingly, administration of antigen to a mucosal surface can often suppress the ability of serum to develop an IgG response to the same antigen. This dichotomy between the systemic and mucosal humoral immune systems reflects the different antigen processing mechanisms, different regulatory T cells and different inherent capabilities of the B lymphocytes in the specific locations.

Peyer's patches, isolated lymphoid follicles and the appendix are structures included as part of the gut-associated lymphoid tissues (GALT). Since mesenteric lymph nodes (MLN) also contain the same precursor lymphoid cells, they are also included as part of GALT despite their less intimate association with the gut lumen. They may, however, merely be serving as waystations for

lymphocytes which are passing from the intestine to the systemic circulation.

Many studies on mucosal lymphocytes have been performed using Peyer's patch lymphocytes. Peyer's patches are grossly identifiable aggregates of lymphoid nodules which occur on the antimesenteric border of the small intestine; they are most prominent in the terminal ileum. In experimental animals, Peyer's patches can be detected about halfway through gestation. The lymphoid tissue in the Peyer's patch proliferates rapidly in the fetus. At birth, Peyer's patches have the greatest density of proliferating lymphoid cells in the body (2). The increase in size and number of these structures after birth reflects the initial response of the mucosal immune system to the environmental antigens, especially microbial flora as germ-free animals have small Peyer's patches which enlarge after the animals are exposed to microorganisms (3). The large follicular areas of Peyer's patches are rich in B lymphocytes that mainly express surface IgM and serve as precursors for IgA secreting plasma cells (4). The dome-corona area located just above the follicles and beneath the surface epithelium contains B cells, T helper cells, macrophages and cells expressing the Ia class II surface antigen (5).

Isolated lymphoid follicles are found throughout the gastrointestinal tract and are the most abundant discrete lymphoid structure of GALT. There is evidence that they have similar functions to Peyer's patches. First, the overlying surface epithelium contains the same specialized cells (M cells) for sampling luminal antigens as are found over Peyer's patches. Second, extirpation or exclusion of Peyer's patches does not signficantly interfere with antigen processing in experimental models of mucosal immunity. This implies that isolated follicles may contain similar antigen precursor cells as Peyer's patches (6).

Lymphocytes with specific functions selectively populate defined anatomic compartments in the mucosa. Interepithelial lymphocytes (IEL) and lamina propria lymphocytes (LPL) are distinct populations with vastly different functions. IEL within absorptive epithelium in the small intestine and colon consist mainly of T lymphocytes which express surface antigens associated with suppressor/cytotoxic function (CD8) (7). Cytotoxic activities of mucosal lymphocytes are, in general, weaker than those of corresponding peripheral blood lymphocytes. However, antibody-dependent cell-mediated cytotoxicity (ADCC), natural killing (NK), and mitogen-induced cellular cytotoxicity (MICC) have all been demonstrated with mucosal lymphocytes. Under experimental conditions, an ADCC mechanism has been shown to function with secretory IgA directed against Shigella flexneri and Salmonella typhi

(8). Considering the proximity of IEL and secretory IgA, it is tempting to speculate as to the importance of this ADCC mechanism.

The specialized surface epithelial cells which serve as the portal of entry for intraluminal antigens have been termed "M" (membraneous) cells. They are located within the follicle-associated epithelium (FAE) which overlie the dome region of lymphoid follicles in Peyer's patches, tonsils, the appendix and isolated lymphoid follicles throughout the gut (11). When specific pathogen-free mice are transferred to a conventional animal house setting, a threefold increase in M cells was measurable after 1 week (12). M cells are interspersed among absorptive epithelial cells and rare goblet cells

The designation of these specialized surface epithelial cells as membraneous (M) cells by Owen aptly describes the flat appearance of these cells (13). Their surface has broad irregular microvilli distinct from adjacent absorptive cells. Macromolecules, viruses, bacteria and protozoa have been shown to be taken-up from the intestinal lumen by M cells. With macromolecules, following attachment to the surface epithelium, they are quickly packaged into pinocytotic vescicles and transported to adjacent lymphocytes or to the underlying lymphoid follicle. Particulate luminal material such as bacteria are phagocytosed and their subsequent fate depends largely on their pathogenetic capabilities. Invasive microorganisms such as Salmonella, Shigella, and Reovirus can escape the confines of the membrane-lined vescicle within the M cell and proliferate locally producing an ulceration or find their way into the systemic circulation (14-16). Indeed, this may serve as the portal of entry for some pathogens such as Shigella. Other microorganisms which cannot invade or escape the membrane lined vescicles are transported to the underlying lymphoid follicle which is the first step in developing the secretory IgA response.

The mechanism by which M cells attach to and engulf such a wide variety of microorganisms and macromolecules is unclear at the present time. Sneller and Strober have speculated that the thinner glycocalyx over the dome areas allows luminal material to approximate more closely M cells and facilitates binding. Alternatively, or in addtion, M cells might be inherently "stickier" than absorptive epithelium (17).

The major action of secretory IgA is to prevent the colonization of pathogenic microorganisms and their toxic products or their attachment to the mucosa (18,19). While it is known that immunization via a mucosal surface is required to optimize the mucosal immune response, the exact form of antigen or carrier protein needed to achieve a secretory IgA response to most antigens is not known. A few proteins are known to be excellent immunogens for eliciting mucosal immunity. Cholera toxin and shiga toxin are

molecules with both specific binding and toxic activities that consistently elicit strong mucosal immunity (20). Some workers have found that cholera toxin may act as a carrier molecule or as an adjuvant to enhance the secretory IgA response to other antigens or hapten groups (21). Shiga toxin, however, does not have a similar adjuvant activity.

Following the stimulation of antigen-specific B lymphocytes in GALT, these lymphoid cells leave Peyer's patches and travel to mesenteric lymph nodes, the thoracic duct, the spleen and eventually back to the lamina propria of the gut and other mucosal locations (22-24). This route of migration has led to the concept of a common mucosal immune system whereby all mucosal surfaces are primed by oral antigen administration. The entire migration takes only 4-6 days for the primary IgA response and as little as 2 days for an IgA memory response.

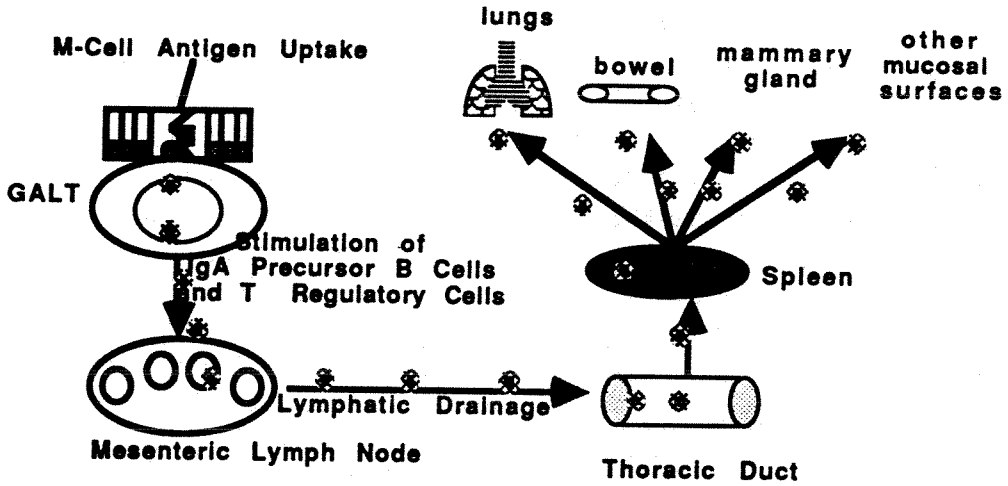

The transportation of secretory IgA across the epithelial cells into the gut lumen requires the unique collaboration of the immunoglobulin product of lymphoid cells (IgA) and a 60,000 dalton glycoprotein product of epithelial cells called secretory component (SC). SC is present in the cytoplasm of the epithelial cells, and its expression can be enhanced by the lymphokine interferon-gamma and by the hormone testosterone (25,26). SC combines with dimeric IgA or multimeric IgM. The IgA-SC complex is packaged into vescicles within the surface epithelium and transported to the luminal surface. This is then released into the gut lumen. The SC protects the IgA from digestion in the proteolytic environment of the gut lumen.

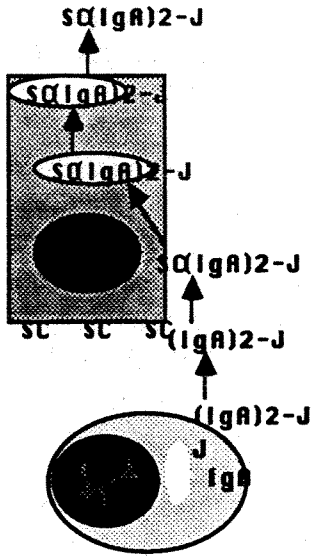

Thus, when examining the pathology of a condition such as IBD, the plasma cell response we see is the result of a complex interaction of lumenal antigens with specific antigen processing cells in the isolated lymphoid follicles so ubiquitous in the large bowel. It is likely that injury to the surface epithelium in IBD allows many more antigens to pass through the surface than one would usually expect, resulting in the increased numbers of plasma cells. In acute self-limited colitis, early-on, one sees only normal numbers of plasma cells due to the acute nature of the injury. After about two weeks, however, a slight increase in the number of plasma cells will be seen due to the primary IgA immune response.

Some workers have high hopes that by looking at the specific content of IgA plasma cells we may learn more about the specific agents which are responsible for diseases like IBD. Whether we achieve this goal or not, understanding the nature of the plasma cell content of the bowel and the process by which the cells arrive there helps us to understand the pathogenesis of some of the biopsies which we examine.

References

1. Hart, S., Wrathmell, A., Harris, J.E.: Gut associated lymphoid tissue in the dogfish Scyliorhinus canicula: a light microscopic study. J. Marine Biol. Assn. 66:721-729,1986.
2. Reynolds, J.D., Morris, B: The evolution and involution of Peyer's patches in fetal and postnatal sheep. Eur. J. Immunol. 13:627-631, 1983.
3. Crabbe, P.A., et al: Immunohistochemical observations on lymphoid tissues from conventional and germ-free mice. Lab. Invest. 22:448, 1970.

4. Tseng, J.: A population of resting IgM-IgD double-bearing lymphocytes in Peyer's patches: the major precursor cells for IgA plasma cells in the gut lamina propria. J. Immunol. 132:2730-2734, 1984.
5. Ermak, T.H., Owen, R.L.: Differential distribution of lymphocytes and accessory cells in mouse Peyer's patches. Anatomical Record 215:144-152, 1986.
6. Keren, D.F., Holt, P.S., Collins, H.H., Gemski, P., Formal, S.B.: The role of Peyer's patches in the local immune response of rabbit ileum to live bacteria. J. Immunol. 120:1892-1898, 1978.
7. Hirata, I., Berrebi, G., Austin, L.L., Keren, D.F., Dobbins, W.O.III.: Immunohistological characterization of intraepithelial and lamina propria lymphocytes in control ileum and colon and in inflammatory bowel disease. Dig. Dis. Sci. 31:593-603, 1986.
8. Tagliabue, A., Nencioni, L., Villa, L., Keren, D.F., Lowell, G.H., Boraschi, D.: Antibody-dependent cell-mediated antibacterial activity of intestinal lymphocytes with secretory IgA. Nature 306:184-185, 1983.
9. Royer, H.D., Reinherz, E.L.: T lymphocytes: ontogeny, function, and relevance to clinical disorders. New Engl. J. Med. 317:1136-1142, 1987.
10. London, S.D., Rubin, D.H., Cebra, J.J.: Gut mucosal immunization with reovirus serotype 1/L stimulates virus-specific cytotoxic T cell precursors as well as IgA memory cells in Peyer's patches. J. Exp. Med. 165:830-847, 1987.
11. Rosner, A.J., Keren, D.F.: Demonstration of M-cells in the specialized follicle-associated epithelium overlying isolated follicles in the gut. J. Leukocyte Biol. 35:397-404, 1984.
12. Smith, M.W., James, P.S., Tivey, D.R.: M cell numbers increase after transfer of SPF mice to a normal animal house environment. Am. J. Pathol. 128:385-389, 1987.
13. Owen, R.L.: Sequential uptake of horseradish peroxidase by lymphoid follicle epithelium of Peyer's patches in the normal unobstructed mouse intestine: an ultrastructural study. Gastroenterology 72:440-451, 1977.
14. Marcial, M.A., Madara, J.L.: Cryptosporidium: cellular localization, structural analysis of absorptive cell-parasite membrane-membrane interactions in guinea pigs, and suggestion of protozoan transport by M cells. Gastroenterology 90:583-594, 1986.
15. Rubin, D.H., Kornstein, M.J., Anderson, A.O.: Reovirus serotype I intestinal infection: a novel replicative cycle with ileal disease. J. Virol. 53:391-398, 1985.

16. Wassaf, J.S. Keren, D.F, Mallous,J.L.: Role of M cells in initial antigen uptake and in ulcer formation in the rabbit intestinal loop model of shigellosis. Infect. Immun. 57:858-8863, 1989.
17. Sneller, M.C., Strober, W.: M cells and host disease. J. Infect. Dis. 154: 737-741, 1986.
18. Fubara E.S., Freter, R.: Protection against enteric bacterial infection by secretory IgA antibodies. J. Immunol. 111:395-400, 1973.
19. Williams, R.C., Gibbons, R.J.: Inhibition of bacterial adherence by secretory immunoglobulin A: a mechanism of antigen disposal. Science 177:697-699, 1972.
20. Keren, D.F., Brown, J.E., McDonald, R.A., Wassef, J.S. Secretory immunoglobulin A response to shiga toxin in rabbits: kinetics of the initial mucosal immune response and inhibition of toxicity in vitro and in vivo. Infection and Immunity 57:1885-1889, 1989.
21. Elson, C.O., Walding, W.: Generalized systemic and mucosal immunity in mice after mucosal stimulation with cholera toxin. J. Immunol. 132:2736-2741, 1984.
22. Roux, M.E., McWilliams, M., Phillips-Quagliata, J.M., Lamm, M.E.: Differentiation pathways of Peyer's patch precursors of IgA plasma cells in the secretory immune system. Cell. Immunol. 61:141-153, 1981.
23. Tseng, J.: Expression of immunoglobulin heavy chain isotypes by Peyer's patch lymphocytes stimulated with mitogens in culture. J. Immunol. 128:2719-2725, 1982.
24. Weisz-Carrington, P., Roux, M.E., McWilliams, M., Phillips-Quagliata, J.M., Lamm, M.E.: Hormonal induction of the secretory immune system in the mammary gland. Proc. Natl. Acad. Sci. USA 75:2923-2931, 1978.
25. Sollid, L.M., Kvale, D., Brandtzaeg, P., Markussen, G., Thorsby, E.: Interferon-gamma enhances expression of secretory component, the epithelial receptor for polymeric immunoglobulins. J. Immunol. 138:4303-4306, 1987.
26. Sullivan, D.A., Allansmith, M.R.: Hormonal influence on the secretory immune system of the eye: androgen modulation of IgA levels in tears of rats. J. Immunol. 134:2978-2982, 1985.

GASTROINTESTINAL PATHOLOGY SOCIETY

MARCH 17, 1991

1:30 - 5:00 P.M.

COLORECTAL NEOPLASIA

MODERATOR: Daniel G. Sheahan, M.B., M.Sc.
University of Pittsburgh
School of Medicine
Pittsburgh, PA

1:30 p.m. **National Polyp Study: A Progress Report** - M.J. O'Brien, M.D., L.S. Gottlieb, M.D., S. Sternberg, M.D., A. Zauber, M.D. S.J. Winawer, M.D., and the NPS Work Group.

2:00 p.m. **Dysplasia/Carcinoma Complicating Ulcerative Colitis** - Rodger Haggitt, M.D., University of Washington Medical Center, Seattle, WA.

2:30 p.m. **Genetic Epidemiology of Adenomatous Polyps and Colon Cancer** - Randall Burt, M.D, Universi of Utah School of Medicine, Salt Lake City, Utah.

3:00 p.m. **Coffee Break**

3:30 p.m. **Molecular Biology and the Etiology of Colorect Carcinoma** - Stanley Hamilton, M.D., Johns Hopk School of Medicine, Baltimore, Md.

4:00 p.m. **Clonal Molecular Genetic Changes in Colorecta Carcinoma as Determinants of Tumor Behavior** - Scott Kern, M.D., Johns Hopkins School of Medicine, Baltimore, Md.

4:30 p.m. **DNA Quantitation in Colon Carcinoma: Does It Predict Clinical Outcome?** - John Crissman, M Wayne State University, Detroit, Michigan.

National Polyp Study: A Progress Report

M.J. O'Brien, L. S. Gottlieb, S.S. Sternberg, A. Zauber, S.J. Winawer and the NPS Work Group. Memorial Sloan Kettering Cancer Center, New York and Mallory Institute of Pathology, Boston, MA.

The National Polyp Study is a multicenter randomized clinical trial designed to compare the efficacy of various follow up intervals for detecting metachronous adenomas. During the decade 1980-90, 1422 patients have been randomized to two arms, A with colonoscopy at year 1 and year 3, and B with an examination at year 3 only, following initial clearing of the colon of all polyps. Patients in both arms have a repeat examination at 6 years. The cohort has now been followed for a mean of 5.2 years.

There is a central review process by a 3 member Pathology Review Committee, for the classification of index and metachronous adenomas. The pathology database currently includes more than 10,000 polyps from approximately 5000 patients (randomized and non-randomized). Adenomas represented 66.5% of the polyps in this clinical cohort, and 87% of these showed a tubular histology, 5% showed high grade dysplasia and 1.5% focal invasive adenocarcinoma. Hyperplastic polyps represented 11% of all colorectal polyps. Analysis of the pathology database to date has focused on patient and polyp determinants of high grade dysplasia in adenomas, the relevance of bowel location to adenoma evolution, the temporal sequence of adenoma progression to invasive adenocarcinoma and the association of hyperplastic polyps and adenomas.

As of the end of 1989, 49.5% of patients were randomized to arm A and 50.5% to arm B. Metachronous adenomas were found at year 1 in 29% of patients (Arm A) and at year 3 in 22% (Arm A) and 32% (Arm B) respectively. The corresponding figures for re-examinations at 6 years was 15% (Arm A) and 23% (Arm B). The effect of clearing the colon twice on follow-up is reflected in the adenoma recurrence rate for arm A at 3 years and arm B at 6 years. These figures are likely to most accurately represent the true frequency of metachronous adenomas. Risk factors for metachronous adenomas are patient age (> 60 yrs), size of initial adenoma and multiplicity of enrollment adenomas. When metachronous adenomas occur within the study timeframe they tend to be small, of tubular histology, rarely show high grade dysplasia and are evenly distributed throughout the colon and rectum.

The ongoing study has already contributed to the emergence of conservative practice guidelines for performance of colonoscopy in patients with colorectal adenomas and has provided a scientific basis for this approach. It has highlighted the important role of accurate pathologic classification of polyps for the conduct of such a study and for the appropriate and cost-effective management of patients who undergo colonoscopic polypectomy.

DYSPLASIA/CARCINOMA COMPLICATING ULCERATIVE COLITIS

Rodger C. Haggitt, M.D.

Abstract

Patients with long-standing, extensive ulcerative colitis have an increased risk of colorectal cancer. The exact magnitude of the cancer risk and what should be done about it are controversial. The acceptable management options include "prophylactic" colectomy after 10 years of disease or colonoscopic biopsy surveillance for dysplasia or early cancer. The rationale for biopsy surveillance is based on the concept that cancer in ulcerative colitis evolves through a premalignant phase of dysplasia that can be detected on biopsy and which identifies the patient who requires a colectomy for cancer prevention, even if the colitis is clinically asymptomatic. Dysplasia is defined as neoplastic transformation of the colonic epithelium that remains confined within the basement membrane of the gland within which it arose. Dysplasia comprises a continuous spectrum of epithelial abnormalities ranging from minimal atypism to cytologically malignant. Dysplasia has been subdivided into low- and high-grade based on the degree of atypism present, but because the abnormalities constitute a spectrum, the boundaries between low-grade and high-grade dysplasia are not sharply defined and there is therefore intra- and interobserver variation in its grading. The diagnosis of dysplasia is complicated by active inflammation that induces reactive and regenerative changes which may closely mimic neoplastic transformation.

The efficacy of the biopsy surveillance method for reducing cancer risk in patients with ulcerative colitis has not yet been conclusively demonstrated, but the results of several long term, prospective follow-up studies look promising. Problems with the use of dysplasia as a marker for cancer risk in the management of patients include the difficulty in its diagnosis when active inflammation is present, the intra- and interobserver variation in its diagnosis and grading, the difficult in adequately sampling the mucosa, and perhaps as a

consequence of inadequate sampling, the development of cancer in some patients who have no dysplasia detected in their biopsies.

For these reasons, numerous attempts have been made to identify objective "markers" for increased cancer risk in ulcerative colitis. With the exception of flow cytometry for analysis of nuclear DNA content and cell cycle parameters, none of these "markers" has proven valuable. The presence of aneuploid populations of cells correlates reasonably well with the histologic diagnosis of dysplasia and preliminary studies suggest that it can select patients who do not have dysplasia but who are at risk for progressing to develop it.

REFERENCES

1. Ekbom A, Helmick C, Zack, Adami HO: Ulcerative colitis and colorectal cancer. A population-based study. *N Eng J Med* 1990;323:1228-1233.
2. Lennard-Jones JE, Melville DM, Morson BC, et al: Precancer and cancer in extensive ulcerative colitis: findings among 401 patients over 22 years. *Gut* 1990;31:800-806.
3. Nugent FW, Haggitt RC: Results of a long term prospective surveillance program for dysplasia in ulcerative colitis. *Gastroenterology* 1991 (In press).
4. Riddell RH, Goldman H, Ransohoff DF, et al: Dysplasia in inflammatory bowel disease: Standardized classification with provisional clinical implications. *Hum Pathol* 1983;14:931-968.
5. Lofberg R, Brostrom O, Karlen P, et al: Colonoscopic surveillance in long-standing total ulcerative colitis - a 15-year follow-up study. *Gastroenterology* 1990;99:1021-1031.
6. Melville DM, Jass JR, Shepherd NA, et al: Dysplasia and deoxyribonucleic acid aneuploidy in the assessment of precancerous changes in chronic ulcerative colitits. *Gastroenterology* 1988;95:668-675.

uccomplabs

GENETIC EPIDEMIOLOGY OF ADENOMATOUS POLYPS AND COLON CANCER

RW Burt[1], DT Bishop[2], L Albright[3], WS Samowitz[4], JA DiSario[1], MH Skolnick[3]

Depts. of Medicine[1], Medical Informatics[3] and Pathology[4], University of Utah College of Medicine, Salt Lake City, Utah, and Imperial Cancer Research Fund[2], Leeds, England.

Well characterized inherited colon cancer syndromes include familial adenomatous polyposis, Gardner syndrome and hereditary nonpolyposis colon cancer. Familial adenomatous polyposis and Gardner syndrome are autosomal dominantly inherited conditions characterized by hundreds to thousands of colonic adenomas which usually begin to appear in the second decade of life. Colon cancer occurs at an average of 39 years and is inevitable if the colon is not removed. Both syndromes also exhibit gastric and small bowel polyps in a large fraction of affected individuals. Proximal gastric polyps are "fundic gland polyps" which have no malignant potential. Small bowel polyps are adenomas and are most often observed in the periampullary area of the duodenum. These polyps have some malignant potential as a 10 to 12 percent lifetime risk for duodenal cancer is found in individuals with these syndromes. Gardner syndrome differs from familial adenomatous polyposis in that extraintestinal growths also are observed, including osteomas, epidermoid cysts, dental abnormalities, desmoids and congenital hypertrophy of the retinal pigment epithelium. Both familial adenomatous polyposis and Gardner have mapped to the "FAP locus" on the long arm of chromosome 5. The syndromes are rare and together account for less than one percent of colon cancer cases.

Hereditary nonpolyposis colon cancer includes site specific colon cancer and family cancer syndrome. Both syndromes are autosomal dominantly inherited conditions characterized by a high occurrence of colon cancer at a young age and an excess of proximal colonic tumors. Adenomatous polyps are present in affected individuals, but are few in number. Thus, it is difficult to distinguish a single affected individual from one with "sporadic" adenomas. Family cancer syndrome includes ovarian, uterine and possibly breast cancer in addition to colon cancer. The nonpolyposis syndromes are more common than the polyposis syndromes and account for approximately 6% of colon cancer cases.

The remainder of individuals with colonic adenomatous polyps or colon cancer are often referred to as "sporadic" cases. Numerous studies have shown, however, that first-degree relatives of those with sporadic colon cancers and adenomas are at a 2- to 3-fold increased risk for colon cancer. It has been hypothesized that this familial risk occurs on the basis of shared environmental factors, multifactorial inheritance or partially penetrant mendelian inheritance.

To determine the cause of familial risk in sporadic cases, we examined the occurrence and kindred distribution of adenomatous polyps in asymptomatic individuals from numerous kindreds (NEJM 1988;319:533). Kindreds were selected through an individual with an adenomatous polyp or a sibling pair with colon cancer. No mendelian patterns of cancer were observed and no features of the known syndromes of colon cancer were present. Family members and spouse controls were studied by 60-cm flexible proctosigmoidoscopy for the presence of colonic neoplasms. We studied 670 individuals from 34 kindreds. Adenomas were found in 78 of 407 family members (19%) and in 32 of 263 spouses (12%). Pedigree analysis by likelihood methods gave strong evidence for partially penetrant, dominantly inherited susceptibility to colorectal adenomas and cancers. Under the most likely model, the gene frequency for the susceptibility gene or genes was 19%. The analysis also suggested that adenomas and cancers developed only in susceptible individuals, but the 95 percent confidence limits of this result varied from 53 to 100%. We hypothesize from these results that inherited factors determine individual susceptibility to adenomatous polyps and colon cancer, while environmental factors determine the expression of the partially penetrant susceptibility genes.

Further work includes genetic mapping studies in the kindreds examined. It is hoped that the partially penetrant susceptibility genes suggested by the genetic epidemiology studies can be mapped and eventually characterized. Gene environment interaction studies are also proposed to determine how environmental factors affect genetic susceptibility to give rise to polyps and eventually cancer. We also are examining individual risk of adenomatous polyps in relatives of individuals with adenomatous polyps or colorectal cancer. Such risk determinations are important for establishing appropriate cancer screening in relatives until gene markers are available.
(Supported by NIH grants CA-28854, CA-40641, and RR-64.)

MOLECULAR BIOLOGY AND THE ETIOLOGY OF COLORECTAL CARCINOMA

Stanley R. Hamilton, M.D.
Department of Pathology and Oncology Center
The Johns Hopkins University School of Medicine and Hospital
Baltimore, MD 21205

The etiology of colorectal carcinoma is not yet known. Current evidence indicates that both environmental factors, particularly diet, and inheritance play important roles. Numerous studies have implicated high dietary fat, low dietary fiber, and low dietary levels of various vitamins and trace metals as etiologic factors. Epidemiologic evidence indicates different environmental influences on the etiology of carcinomas of the right colon, the left colon, and the rectum. The incidence rates of rectal cancer vary relatively little around the world whereas the incidence of colonic carcinoma varies widely. Countries with high incidence of colonic carcinoma usually have a high proportion of carcinomas in the left colon as compared with the right colon.

In addition to environmental factors, inheritance is important. Two autosomal dominant syndromes are recognized to produce colorectal carcinoma. Adenomatous polyposis syndrome is characterized by hundreds to thousands of colorectal carcinomas and leads to carcinoma mainly in the left colon. The other syndrome, hereditary nonpolyposis colorectal cancer syndrome, produces few adenomas (hence the term non-polyp<u>osis</u>); carcinoma occurs characteristically in the right and transverse colon in this syndrome. Studies of large pedigrees have suggested that the ability to form colorectal adenomas is also inherited as an autosomal dominant characteristic. Furthermore, the occurrence of colorectal carcinoma in first-degree relatives of patients with that tumor is three to four times higher than the general population.

Molecular biology and molecular genetics may play a role in identifying the precise etiology of colorectal carcinoma. Knudson's hypothesis that the same genes are involved in the genesis of sporadic and inherited forms of a tumor appears to be applicable in colorectal carcinoma. The APC (Adenomatous Polyposis Coli) locus on the long arm of chromosome 5 in region 21 is linked to the syndrome in pedigrees and is also deleted frequently in "sporadic" colorectal carcinomas. The locus for hereditary nonpolyposis colorectal cancer has been linked to the Kidd blood group located on the long arm of chromosome 18. The DCC (Deleted in Colorectal Carcinoma) gene, whose putative product has homology to neural cell adhesion molecule, is also located on the long arm of chromosome 18, raising the possibility that DCC is the

gene for the syndrome. At present, individuals who have inherited the abnormal gene for adenomatous polyposis syndrome can be identified before the appearance of colorectal adenomas through the use of linkage analysis with molecular genetic probes near the APC gene if DNA is available from known affected family members. Identification of the gene(s) for hereditary nonpolyposis colorectal cancer syndrome and for other possible inherited predispositions to colorectal neoplasia offers the possibility of similar identification of high-risk persons.

Interaction among environmental factors, inheritance, and molecular genetics is a fertile area for investigation. At present, there are relatively few clues. Left-sided carcinomas of the large bowel have a significantly higher prevalence of deletion of the short arm of chromosome 17, the site of the p53 gene, as compared with right-sided carcinomas. In addition, the prevalence of DNA aneuploidy by flow cytometry is also higher in left-sided carcinomas. The majority of colorectal carcinomas arise from pre-existing adenomas, providing a unique opportunity to study precursor lesions. Molecular genetic studies of the adenoma-carcinoma sequence have shown increasing prevalence of ras gene mutations, deletion and mutation of the p53 gene, deletion of the DCC gene, and deletion of the locus of the APC gene as the sequence progresses. However, small tubular adenomas, representing the earliest colorectal neoplasms, rarely have identifiable alterations of these types. As a consequence, these molecular genetic alterations may relate more to tumor progression than etiology. By contrast, generalized abnormalities of DNA methylation are evident even in early adenomas. Furthermore, the grossly normal large bowel mucosa of patients with colorectal neoplasia and inherited syndromes which predispose to colorectal neoplasia have increased levels of DNA methyltransferase, an enzyme which plays an important role in DNA methylation.

The application of molecular biology and molecular genetics to the etiology of colorectal cancer is in its infancy. Risk assessment, screening, and early detection may ultimately be improved through this technology.

DNA Quantitation in Colon Carcinoma: Does it Predict Clinical Outcome?

John D. Crissman, M.D., Daniel W. Visscher, M.D., and Wael A. Sakr, M.D.
Department of Pathology, Harper Hospital and Wayne State University
Detroit, MI. 48201

Flow cytometric (FCM) DNA analysis of colorectal adenocarcinoma has received considerable attention during the past five years. The hypothesis of these reports is that clonal abnormalities of DNA content as quantitated by staining with fluorescent dyes, reflects genetic or functional aberrations associated with more aggressive clinical behavior. It is noteworthy that the technology is neither specific for malignancy (adenomas may be DNA aneuploid) nor particularly sensitive. With commonly employed techniques, total DNA content must deviate by approximately five percent in order to be clearly resolved in a DNA histogram.

Two major problems consistent emerge when analyzing the plethora of literature devoted to this topic. First, technical problems encountered in preparing single cell/nuclear suspension are formidable. Most authors isolate tumor cell nuclei from formalin fixed paraffin embedded tissue sections. This is a complex procedure requiring enzymatic digestions, and success is subject to a wide variety of poorly controlled factors, such as length of fixation, conditions of embedding and storage, etc.. Despite numerous refinements, a major problem with this method remains creation of nuclear debris resulting in poorly resolved DNA histograms with wide CV's. In addition to obscuring near diploid or small aneuploid populations, background debris contributes to the synthesis phase region of the histogram resulting in erroneous measurement of SPF. Also, selective loss of aneuploid or rapidly cycling populations occurs, presumably because they are more fragile. Technical aspects of dissociation have been successfully addressed by numerous authors, however, details are often lacking in publications. Moreover, despite an evolving consensus of histogram quality and interpretation, measurement of synthesis phase fractions (SPF) is lacking in most reports, remaining largely as a significant unaddressed issue.

Another serious impediment to determining the clinical value of FCM DNA analysis is that survival data are often not subcategorized by stage, type of therapy or other important prognostic factors (such as colon vs rectal primary), nor are they compared to traditional prognostic pathologic parameters. Table I updates our previous review (2) and reflects the consensus of the articles with sufficient detail allowing comparisons.

Retrospective Series

	5 Yr. Survivors	
	Diploid Range	Aneuploid
Crissman et al (1989) (2) (Pathol Annual Review)	202/308 (66%)	168/386 (44%)
Additional Series (3,4,5,6,7,8)	369/495 (75%)	283/532 (53%)
	571/803 (71%)	451/918 (49%)
Percent ploidy	(47%)	(53%)

Summarizing data from different series is potentially misleading, however, there is an apparent survival advantage for diploid range cancers. This advantage is also found when groups are stratified by Dukes' stage, although the total number of unambiguously defined cases in the literature is meager. There is an even greater paucity of patient series in which standard morphologic and clinical parameters are factored into evaluation of prognosis and compared with ploidy. The best series ((Jass (1989), Fisher (1989), Visscher (1990), Robey-Cafferty (1990), Halvorsen (1990)) for the most part conclude that aneuploid tumors are more often poorly differentiated, higher stage and angio invasive then diploid range tumors. Although these investigators generally found improved five year survivals for patients with diploid range cancers (usually reaching statistical significance in the larger series), DNA content was never as important as tumor stage. Multivariate (regression) analysis, invariably identifies Stage as the most powerful indicator of survival. For the most part, DNA content is one of the lessor contributors to predicting patient outcome, more analogous to grade. Indeed, the difference in survival between patients with diploid range vs aneuploid tumors is generally in the 10-25% range, similar to that predicted by tumor differentiation alone. Thus, although possibly more objective, clinical studies of DNA analysis in colorectal neoplasia have not yet demonstrated that ploidy conveys information different from, and more important than, histopathologic evaluation.

The mechanisms by which FCM aneuploidy confers more aggressive behavior are unclear, although tumors with abnormal DNA content generally have a higher proliferative fraction.(2) One Study (Bauer, 1987) reports SFP in colon cancer and concludes that SPF levels have greater statistical power in predicting patient survival. The data for breast carcinoma also supports the value of SPF as a prognostic parameter. Future studies will likely address this question as well as develop FCM technology to study tumor heterogeneity, response to cytotoxic therapy and preneoplastic diseases.

1. Crissman et al — Mod Pathol, 1:198, 1988
2. Crissman et al — Pathol Ann, 24:103, 1989
3. Kokal et al — Ann Surg, 209:188, 1989
4. Fisher et al — Arch Pathol Lab Med, 113:525, 1989
5. Scivetti et al — Cancer Letters, 46:213, 1989
6. Robey-Cafferty et al — Mod Pathol, 3:261, 1990
7. Halvorsen et al — Scand J Gastroenterol, 25:141, 1990
8. Visscher et al — Mod Pathol, 3:709, 1990
9. Jass et al — J Clin Pathol, 42:254, 1989
10. Bauer et al — Lab Invest, 57:329, 1987

Book Review

Dobbins, William O. III. *Diagnostic Pathology of the Intestinal Mucosa: An Atlas and Review of Biopsy Interpretation.* New York, Springer-Verlag 1990, 217 pp, 124 illustrations.

This book is concerned with the histology and ultrastructural morphology of the mucosa of the small intestine, as seen in per oral biopsies, excluding tumors and states in which "per oral biopsy is not likely to be helpful." Half of it is given over to four chapters which deal with processing of specimens for light and electron microscopy, normal mucosal histology and ultrastructure, and immunohistochemical methods. This includes an interesting and extensive review of the ultrastructural morphology of normal small bowel mucosa. The 'methods' chapters are not aimed at being wide-ranging reviews, but rather they describe procedures currently in use in Dr. Dobbins' laboratory. Of necessity they are highly selective, and some techniques recommended subsequently or illustrated are not described (e.g., the colophonium-Giemsa method for staining coccidia, and immunogold localization of gastrin and somatostatin). The methods for immunoelectron microscopy relate to the *ultrastructural* localization of lymphocyte surface markers - surely an esoteric exercise for most GIPS members.

The second half of the book (Chapter 5) deals with the light microscopic and ultrastructural appearances of pathologically abnormal small bowel mucosa. Dr. Dobbins follows the Rubin classification of these mucosal abnormalities as he did in his chapter in H.T. Norris, ed., *Pathology of the Colon, Small Intestine and Anus* (New York, Churchill-Livingston, pp. 121-65, 1983). The tables are taken directly from that chapter, as are many of the light micrographs. The range of topics covered is comprehensive, including detailed sections on the various forms of sprue, immunodeficiency states, infectious enteritis (including viral, bacterial, fungal, and parasitic infections), lymphangiectasia, injury caused by drugs and irradiation, Crohn's disease, and storage disorders. Each entity is described succinctly, usually with comments of clinical relevance, and most are illustrated at both light microscope and ultrastructural levels. This chapter is the kernel of the book. It is written in a clear and readable style, and the combination of histologic and ultrastructural pathology gives it a dimension which is not available in most texts. The electron micrographs are excellent throughout, as are many of the light micrographs, though some of those taken from the 1983 work have reproduced disappointingly.

To those familiar with Dr. Dobbins' work, this book may bring a sense of *deja vu*, although it is considerably expanded from his earlier publications. About 40% of the references are from the 1980's, the most recent half-dozen being from 1988. The sections on some entities such as microsporidial infection and microvillus inclusion disease ("familial enteropathy") are slightly dated, while a few topics such as hemorrhagic *(E.coli)* enteritis, cytomegalovirus infection simulating graft versus host disease, and the pathology of the duodenum in duodenopancreatic transplants (? excluded because the biopsies are not per oral) are omitted. This is a highly specialized work, of somewhat restricted interest because of its confinement to the pathology of *per oral biopsies of small intestinal mucosa* and its emphasis on ultrastructural pathology.

I enjoyed reading this book, as I enjoyed Dr.Dobbins' monograph on Whipple's Disease, and I will have recourse to both of these volumes. University and Pathology Department libraries should have it as a source of reference.

A. Brian West, M.B., Yale University

BOOK REVIEW: Tao, Liang-Che: *Transabdominal Fine-Needle Aspiration Biopsy,* Igaku-Shoin, New York & Tokyo, 1990

The growing popularity of fine-needle aspiration biopsy (FNAB) as a means for diagnosing abdominal mass lesions has given rise to the need for a useful reference book for pathologists. This book is such a reference, especially useful to those with limited experience with FNAB or in whose practices abdominal aspirates are rarely performed.

Dr. Tao has experience in interpreting over 3800 abdominal FNABs and, in this book, he effectively illustrates significant lesions from all major sites in the abdomen. In the first chapter, he gives a general overview of FNAB, discussing its efficacy, indications, and reliability while stressing the need for obtaining adequate histories and samples. The following chapter outlines procedures and techniques he uses in his practice, including the instruments utilized, processing of material, and smear preparation for rapid analysis. He next describes his general approach to FNAB sampling, which stresses cooperation between the pathologist, radiologist, and clinician in order to optimally use the available information to obtain the most accurate diagnosis, and describes some helpful cytologic criteria common to all sites.

The remainder of the book describes the diagnosis of major lesions in various body sites. Chapter headings include primary retroperitoneal masses, common ovarian lesions, intraperitoneal masses, as well as those describing lesions found in liver,

pancreas, kidney, and adrenal. These subsequent chapters describe the lesions thoroughly, and have good black-and-white photographs to illustrate the findings and short discussions of the problems and pitfalls one may encounter.

The penultimate chapter describes Dr. Tao's approach to the diagnosis of lymphomas, which can be among the most difficult to make by FNAB. He discusses the use of monoclonal antibodies to assist in the diagnosis of non-Hodgkin's lymphomas, and covers the morphology seen on routine preparations.

The final chapter serves as a good overview of monoclonal antibody immunoperoxidase staining techniques and provides a list of antigens that can be used to differentiate various tumors or tissue types. These technical aspects may prove helpful for anyone interested in performing these special procedures in their own practice.

In summary, I highly recommend this book. It is an excellent source of information for practicing pathologists, pathology residents, and cytotechnicians and will be especially useful for those whose experience in FNAB interpretation of the abdomen is limited.

Linda D. Ferrell, M.D.
Associate Professor of Pathology
University of California
San Francisco, CA 94143-0506