GIPS Case of the month

A 50 year-old-female with past history of pulmonary sarcoidosis, gastroesophageal reflux disease and *Helicobacter pylori* gastritis underwent a routine screening colonoscopy. Her last colonoscopy 7 years ago was normal. Colonoscopy revealed a sessile polyp measuring 3 mm in the cecum, which was biopsied. The endoscopic, histologic and key immunohistochemical features of the polyp are demonstrated below.

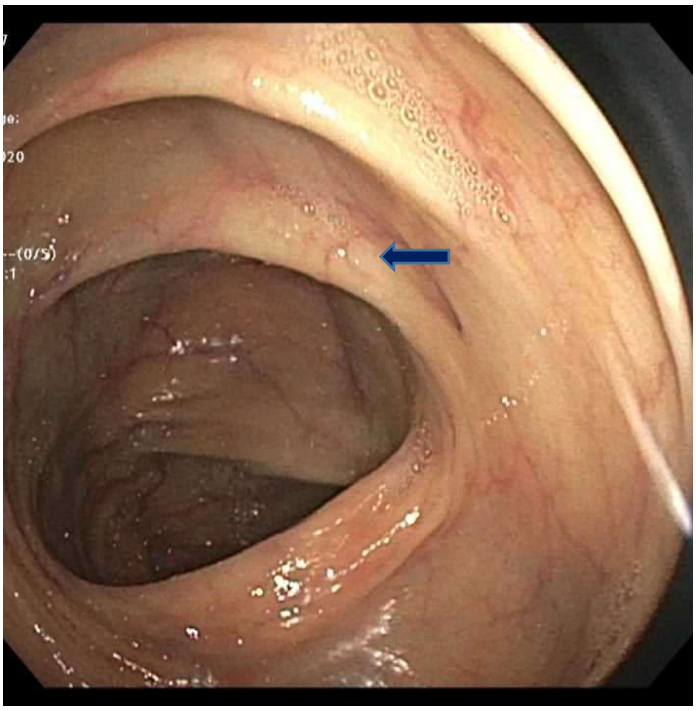

Figure 1: Colonoscopic appearance of the cecal sessile polyp.

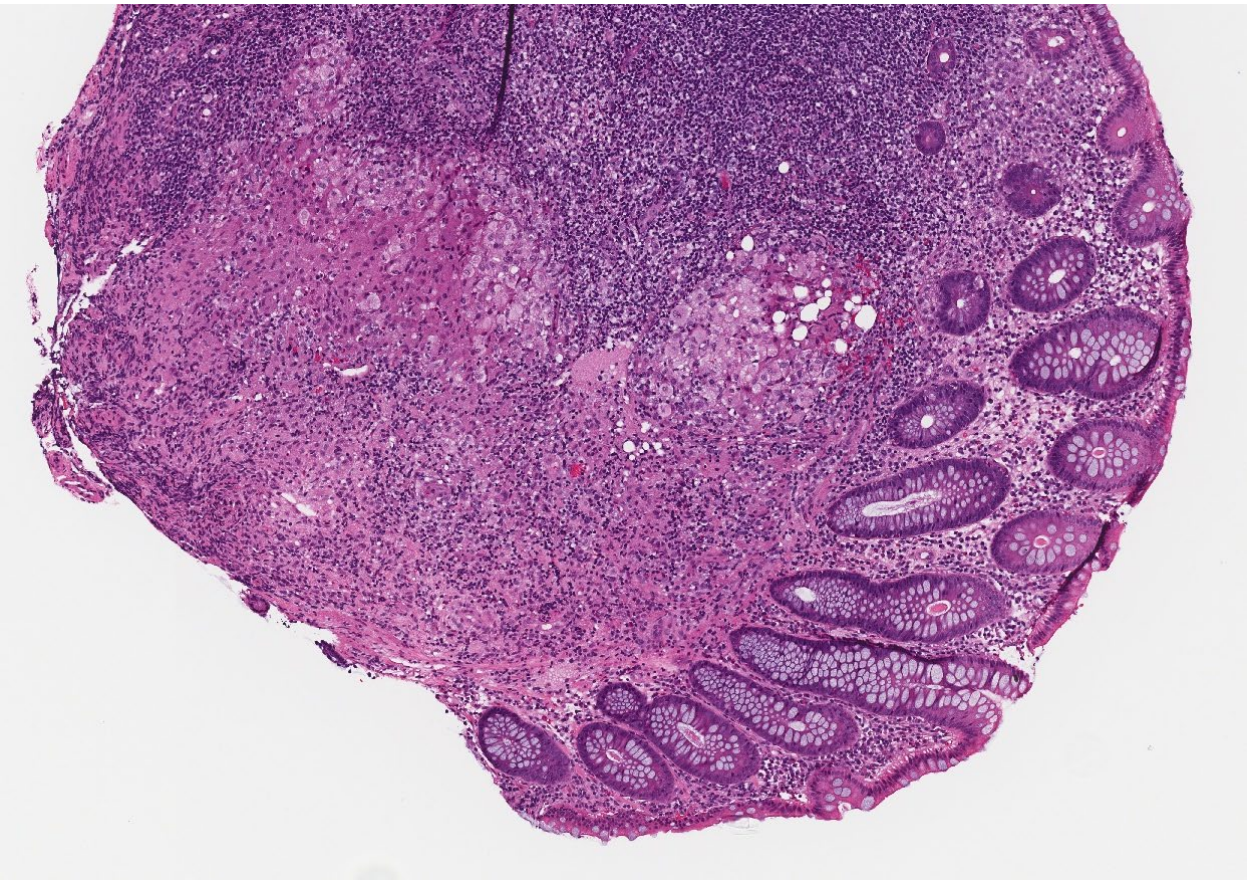

Figure 2: Low power view. Hematoxylin and eosin stain.

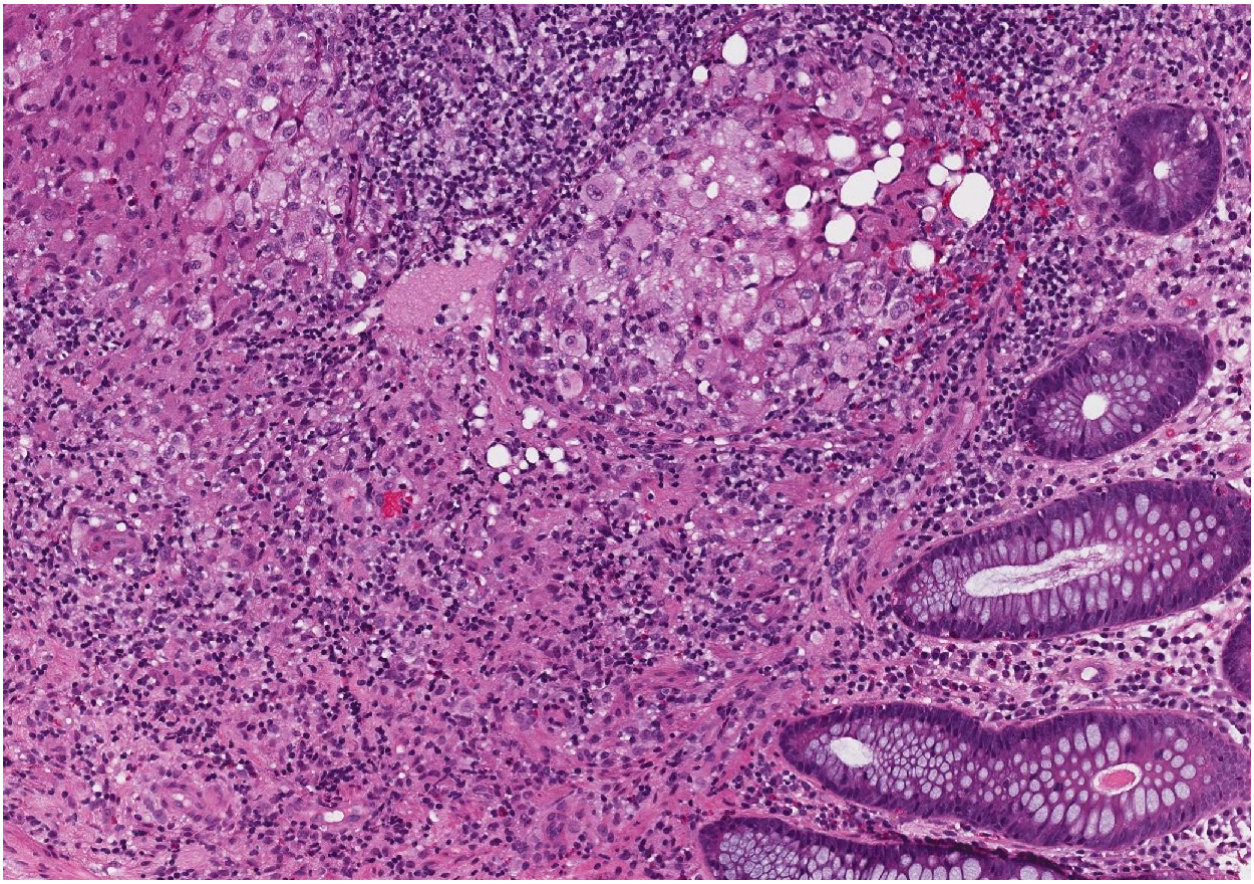

Figure 3: High power view. Hematoxylin and eosin stain.

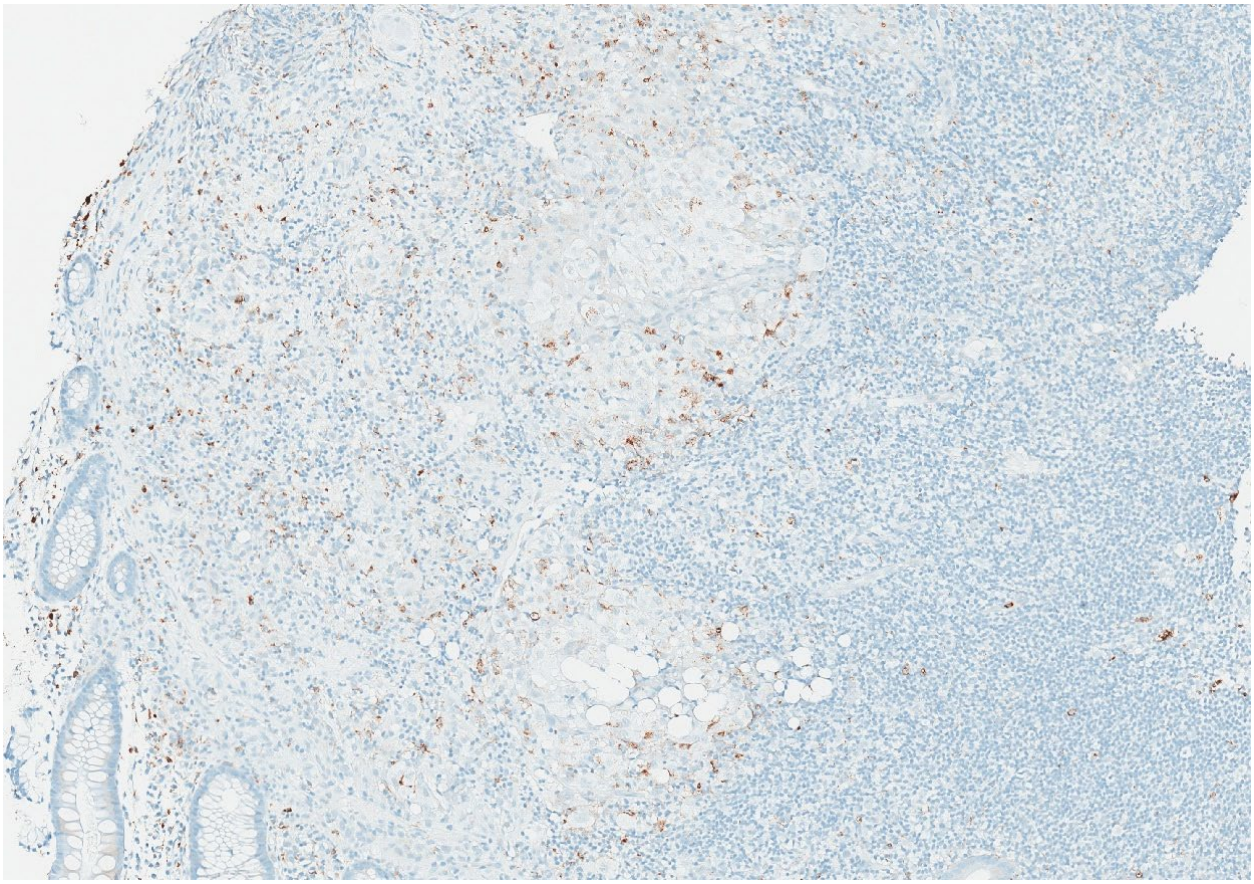

Figure 4: CD68 immunostain.

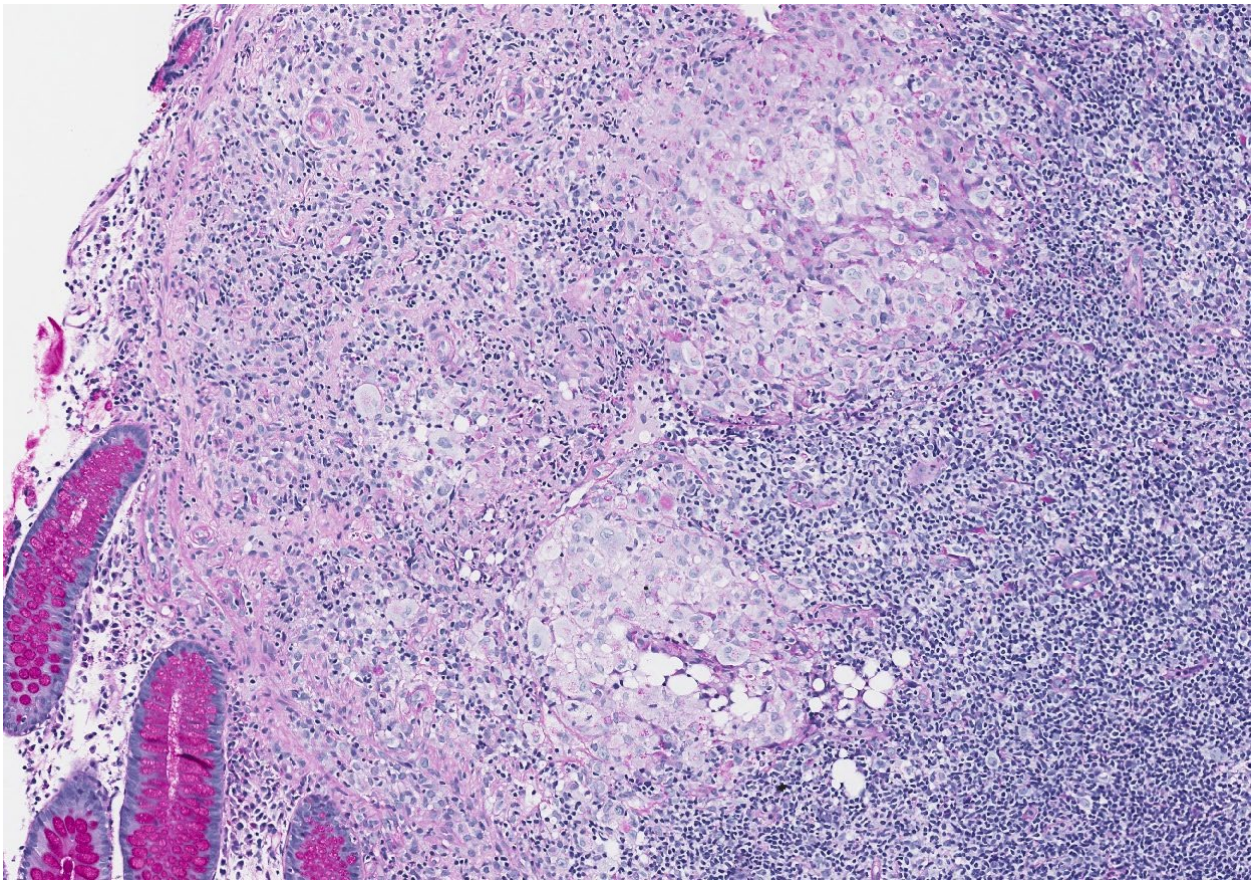

Figure 5: PAS-D stain

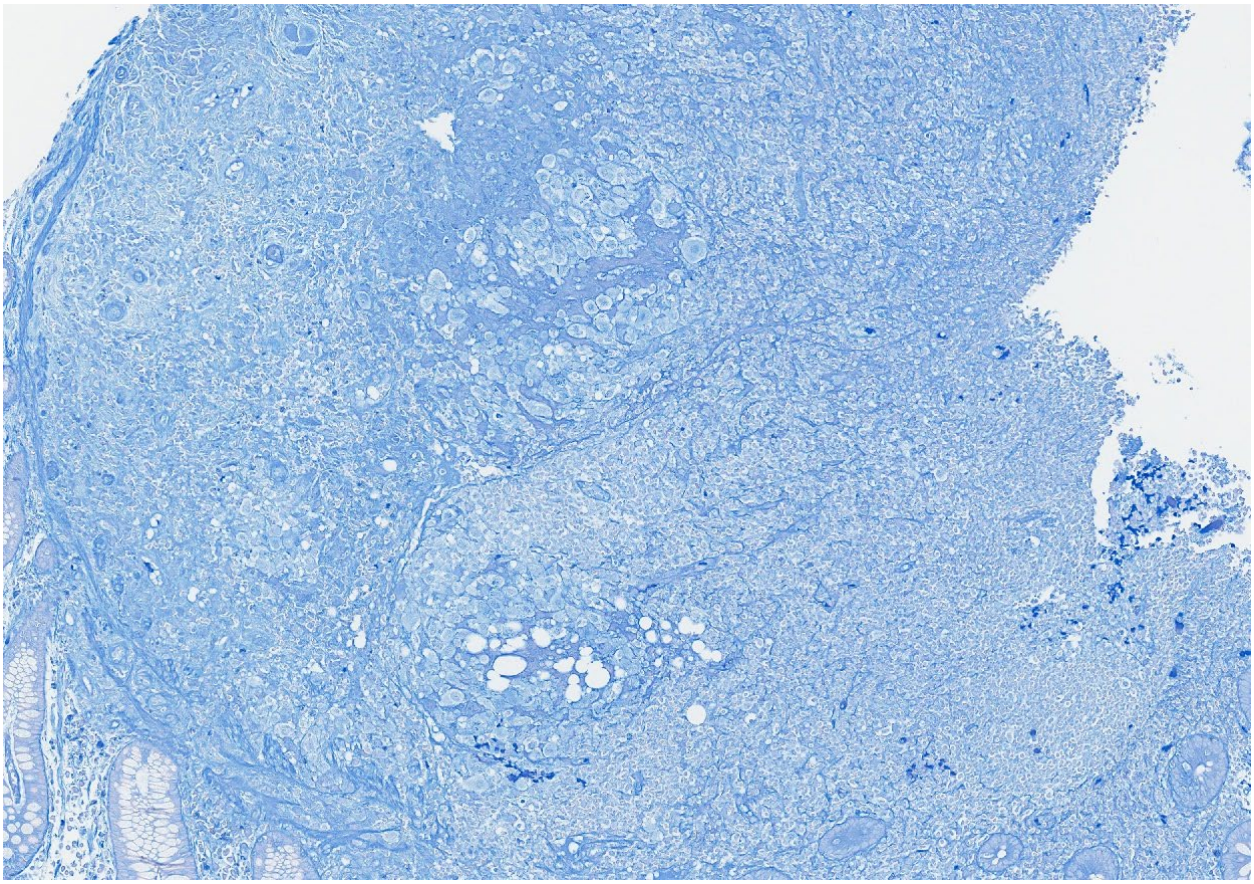

Figure 6: AFB stain.

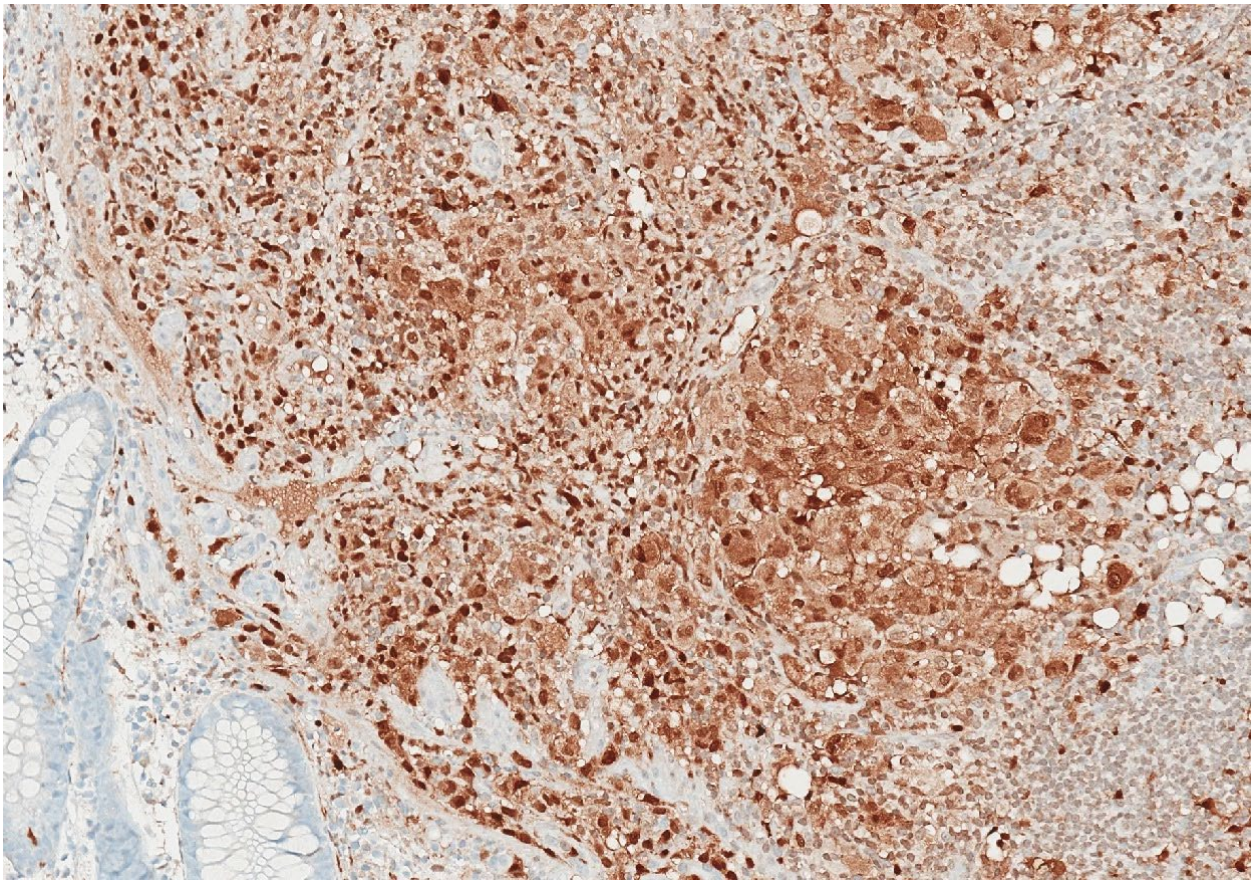

Figure 7: S100 immunostain.

What is the most likely diagnosis?

A. Mycobacterium avium-intracellular complex infection
B. Reactive histiocytosis
C. Langerhans cell histiocytosis
D. Extra-nodal Rosai Dorfman disease
E. Colonic involvement by sarcoidosis

Additional immunohistochemical stains:

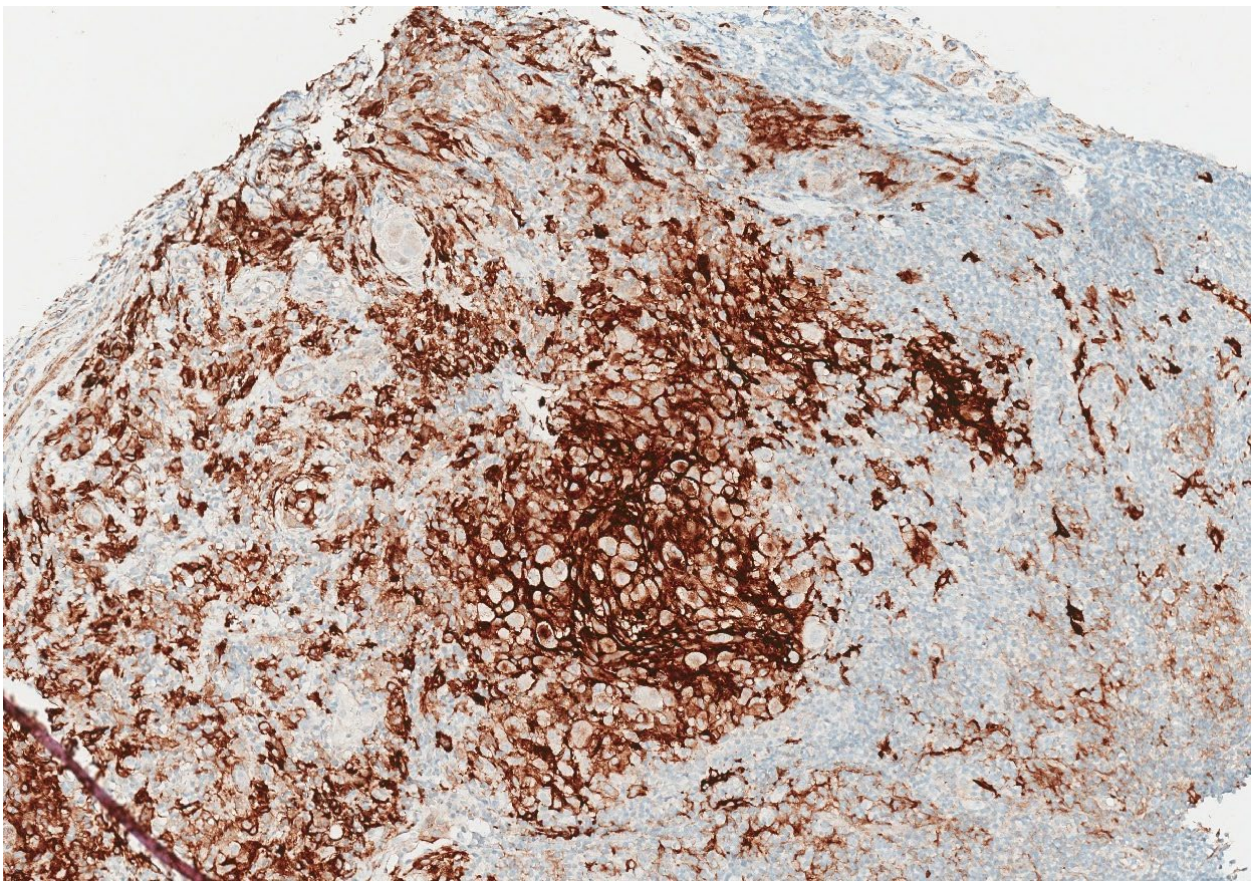

Figure 8: CD1a immunostain.

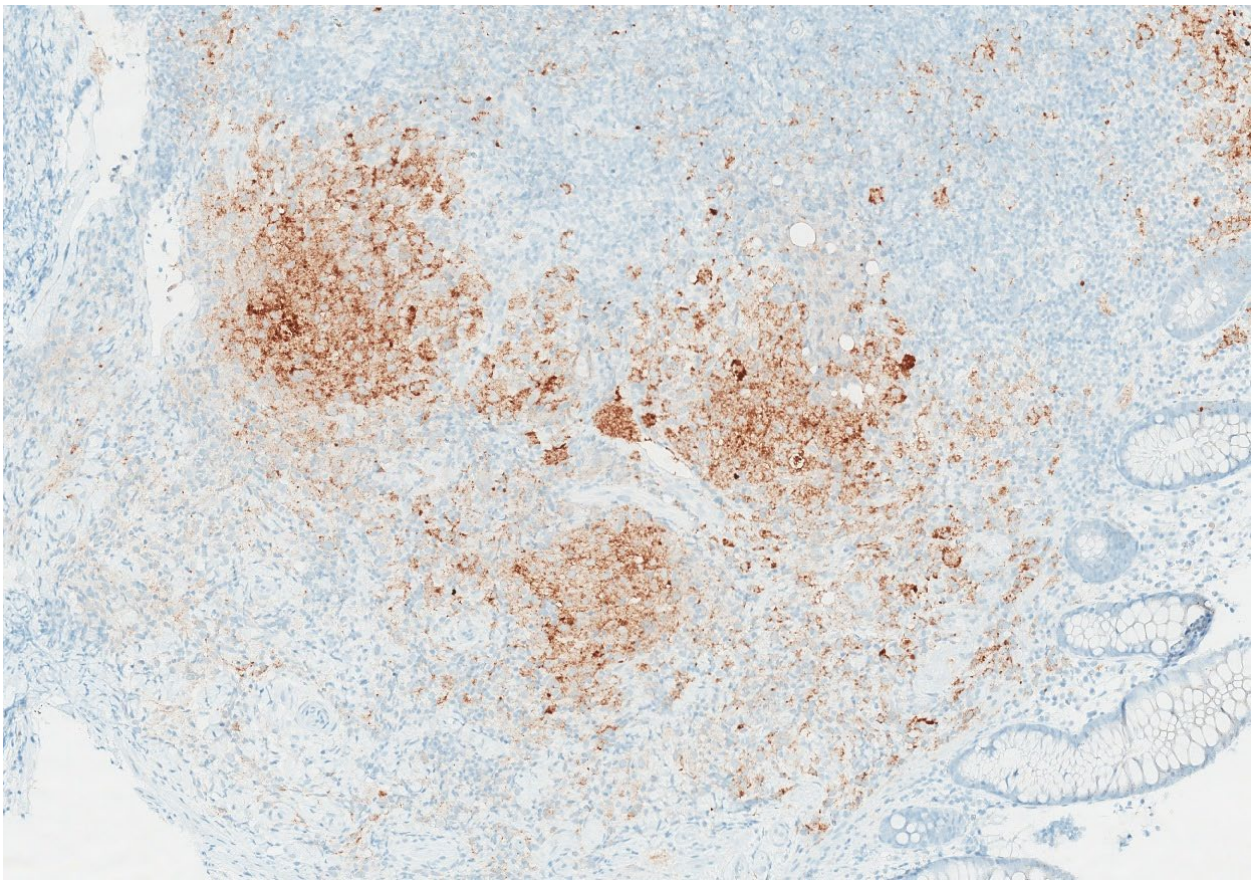

Figure 9: BRAF V600E immunostain.

Correct answer:

C. Langerhans cell histiocytosis

Discussion:

The histologic sections of the cecal polyp demonstrate focal histiocytic aggregates centered in the submucosa with focal extension into lamina propria, associated with prominent lymphoid aggregates. There are only scattered eosinophils present in the lesion. The histiocytic cells are oval in shape and exhibit abundant pale eosinophilic cytoplasm, giving a foamy histiocytic appearance at low power. The nuclei vary from oval to reniform shapes, and contain vesicular chromatin and inconspicuous nucleoli. Nuclear grooves are rarely identified. There are rare mitotic figures. The histiocytic cells were positive for S100, CD1a, and negative for CD68; a Langerin immunostain (not shown) was also positive in histiocytic cells. The findings are diagnostic of Langerhans cell histiocytosis (LCH). BRAF V600E immunostain is positive in the lesional cells (Figure 9), pointing to the fact that some cases of LCH carry BRAF V600E mutation.

LCH is a rare disorder with abnormal clonal proliferation and dissemination of Langerhans-type cells derived from the bone marrow. Colonic involvement by LCH is extremely rare with the majority of cases reported in patients younger than 2 years old at presentation. Young patients usually present with bloody diarrhea, failure to thrive, vomiting and protein-losing enteropathy. Adult patients with colonic LCH are usually asymptomatic, but may present with constipation or anemia. Endoscopic appearance is that of a solitary polypoid or ulcerative lesion. Adults with solitary polypoid LCH have an excellent prognosis, while those with an ulcerative lesion may develop systemic disease.

LCH of the colon, similar to LCH of other locations, shows sheets of medium-sized cells with moderate amount of lightly eosinophilic cytoplasm, convoluted nuclei, intranuclear grooves and inconspicuous nucleoli. There are usually variable number of admixed inflammatory cells like eosinophils and lymphocytes. Immunohistochemistry shows positivity for S100, CD1a, and Langerin (CD207) in the Langerhans cells. The current case exhibits abundant pale eosinophilic cytoplasm and is associated with prominent lymphoid aggregates instead of eosinophils, which is slightly different from classic LCH.

A. The presence of histiocytic cells in the submucosa and lamina propria raises a broad differential including Mycobacterium Avium Intracellular (MAC) complex infection. MAC infection is mostly found in the small intestine of immunocompromised patients and shows sheets of macrophages in the lamina propria filled with the mycobacteria. AFB stain would be positive and the histiocytic cells would be CD68 positive.
B. The presence of histiocytic aggregates in association with prominent lymphoid aggregates also raises the possibility of reactive histiocytosis. However, those cells characteristically express CD68, but lack S100 and CD1a immunoreactivity.
D. Rosai-Dorfman disease of the gastrointestinal tract can also present as a polypoid lesion on endoscopy showing sheets of histiocytic cells in the submucosa. However, their nuclei are round and vesicular, instead of grooved and irregular as seen in LCH. Emperipolesis is commonly seen in Rosai-Dorfman disease. Immunohistochemistry shows positivity for S100 and CD68. However, CD1a and Langerin immunostains are negative.
E. The patient's clinical history of sarcoidosis and presence of histiocytic cells in the submucosa, raises a possibility of colonic involvement by sarcoidosis. However, our case does not show characteristic epithelioid cells or non-caseating granulomata that would be seen in sarcoidosis. The histiocytes in sarcoidosis are positive for CD68 and are negative for CD1a and Langerin. Colonic involvement by sarcoidosis is also rare.

References:

1. Singhi AD, Montgomery EA. Gastrointestinal tract langerhans cell histiocytosis: A clinicopathologic study of 12 patients. Am J Surg Pathol. 2011 Feb;35(2):305-10. doi: 10.1097/PAS.0b013e31820654e4. PMID: 21263252.
2. Feras Zaiem, Rafic Beydoun. Adult Langerhans cell histiocytosis arising in colonic polyp: A case report and literature review. Human Pathology: Case Reports, Volume 17, 2019, 200311 ISSN2214-3300, https://doi.org/10.1016/j.ehpc.2019.200311.
3. WHO Classification of Tumors of the Digestive Tract. 5th edition.

Contributing Authors:

Mrinal Sarwate, M.D.

Pathology Resident

Cleveland Clinic, Cleveland, Ohio

Shaomin Hu, M.D., Ph.D.

Attending Pathologist, Gastrointestinal and Hepatobiliary Pathology,

Cleveland Clinic, Cleveland, Ohio