A 64-year-old male with a history of tubular adenoma with high-grade dysplasia underwent a 3-year surveillance colonoscopy. Four subcentimeter colonic polyps were identified and resected. Histologic examination revealed two tubular adenomas and one hyperplastic polyp. The fourth lesion (Figure 1) was a 5-9 mm sessile polyp.

Figure 1: Endoscopic image of the 5-9 mm sessile polyp.

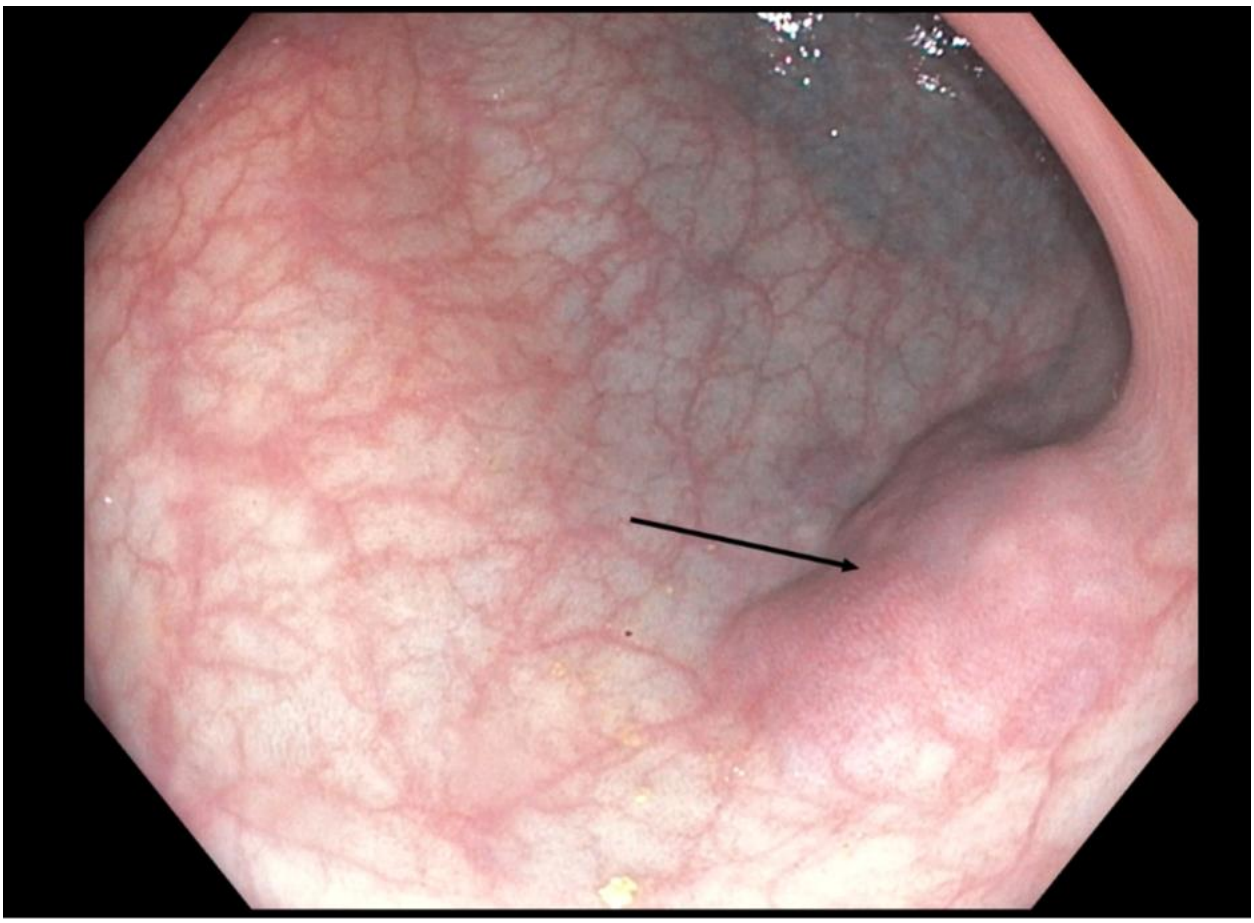

Figure 2: H&E, 20x magnification.

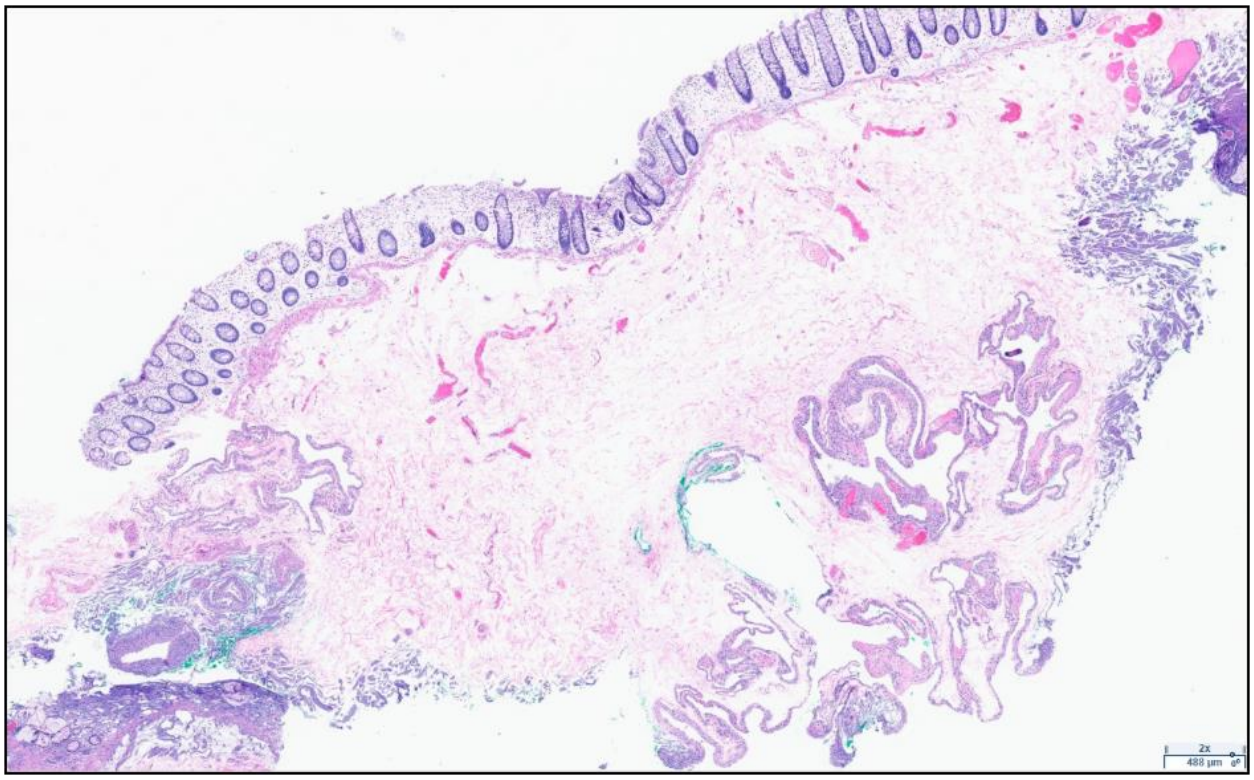

Figure 3: H&E, 220x magnification.

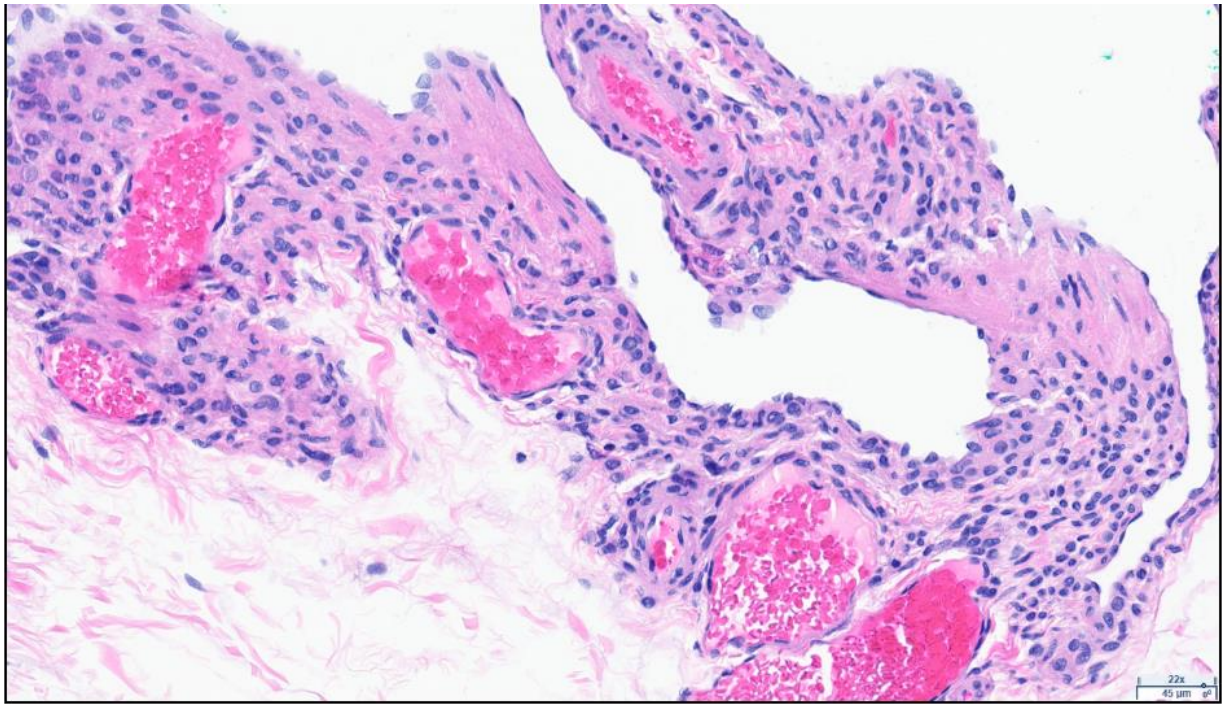

Figure 4: H&E, 400x magnification.

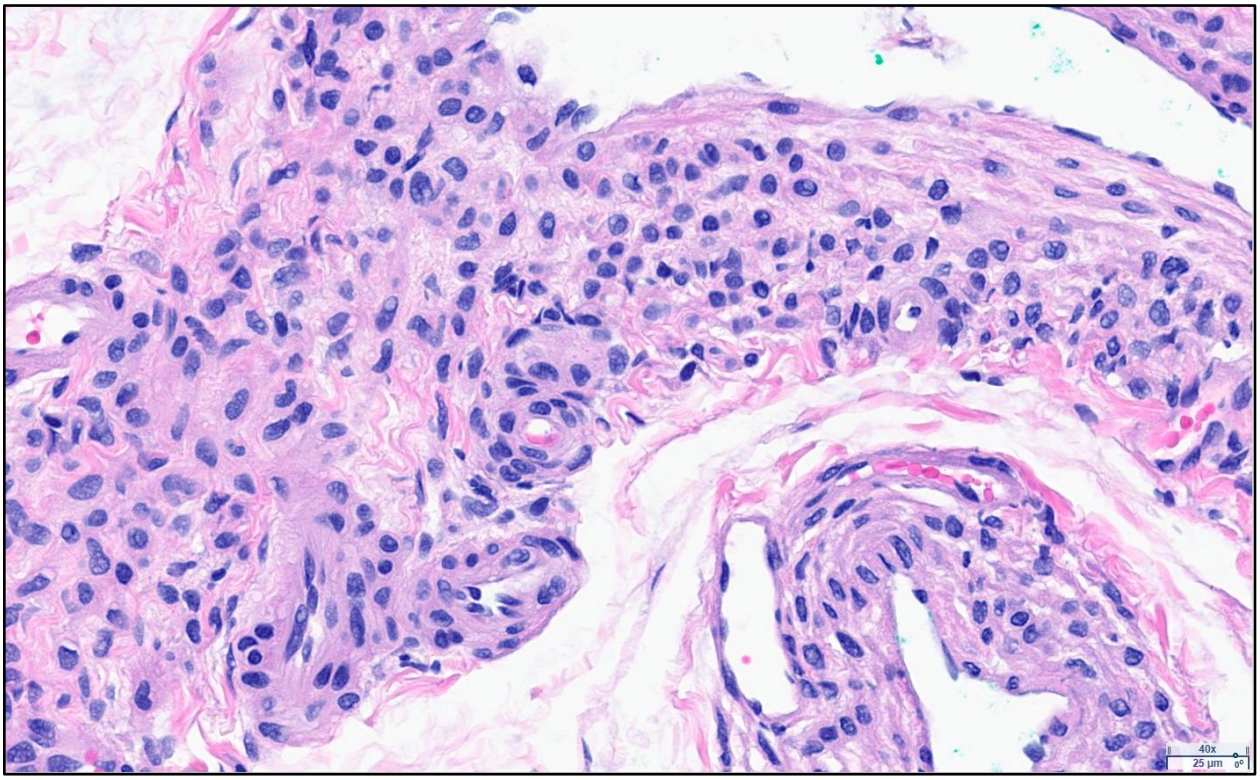

Figure 5: Immunohistochemical profile of the 5-9 mm sessile polyp, 110x magnification. (A) H&E, (B) SMA, (C) Desmin, (D) ERG.

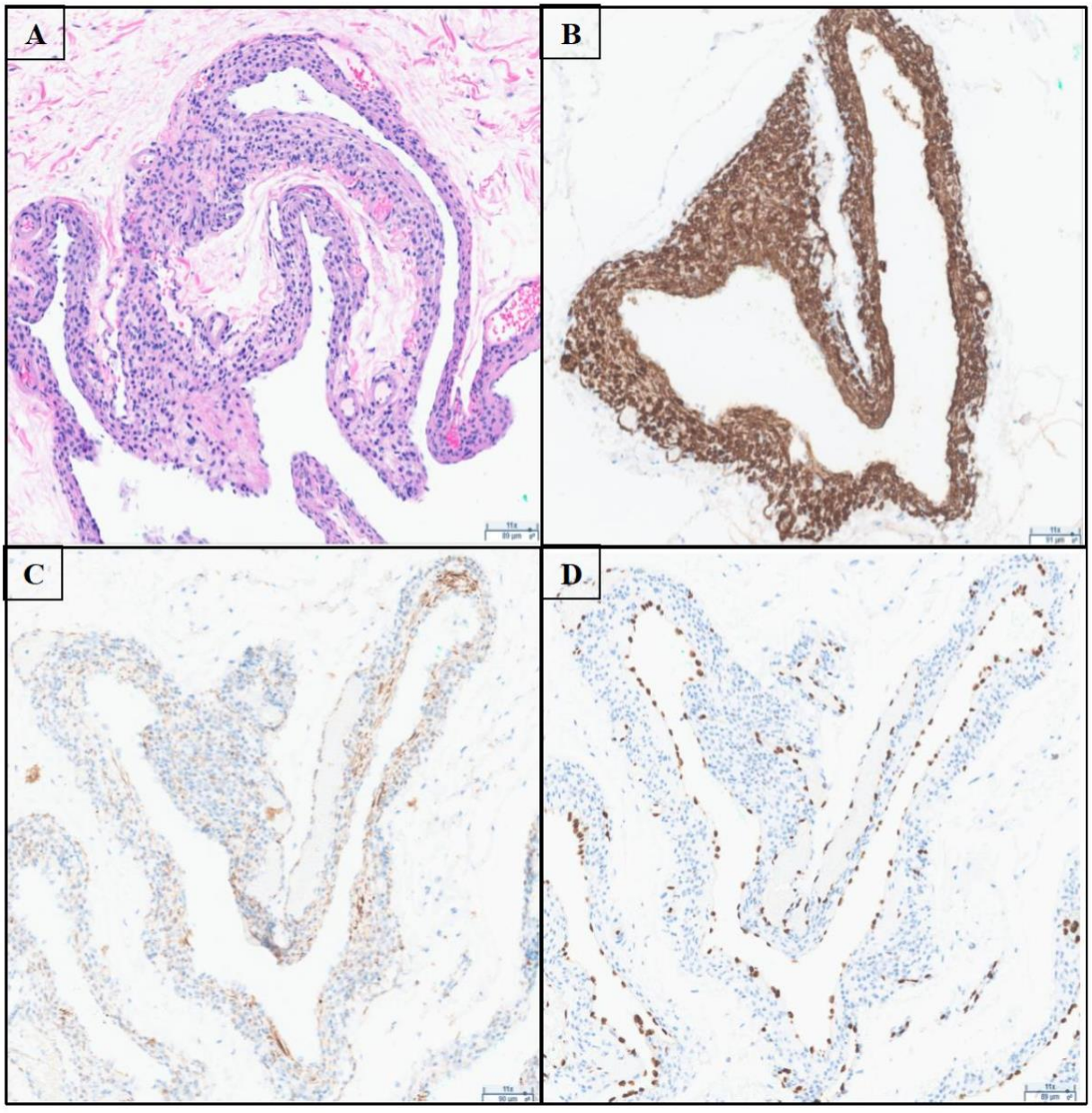

What is the most likely diagnosis?

A. Cavernous hemangioma
B. Arteriovenous malformation
C. Glomangioma
D. Angioleiomyoma, cavernous type
E. Lymphangioma/lymphangiectasia

Correct answer:

C. Glomangioma: Histologic sections reveal clusters of dilated vessels within the submucosa, surrounded by a thin collar of bland ovoid-to-cuboidal cells with monomorphic nuclei (Figures 2-4). The lesional cells demonstrate no cytologic atypia, mitotic activity, or necrosis. The lesional cells are strongly and diffusely positive for SMA but negative for desmin (Figure 5B and 5C). The lesional cells resemble perivascular modified smooth muscle cells of the normal glomus body (glomus cells). ERG highlights the vascular endothelium (Figure 5D). Taken together, these findings are consistent with glomangioma (also described as glomuvenous malformation), a vessel-rich variant of glomus tumor.

Incorrect answers:

A. Cavernous hemangioma: Cavernous hemangioma is a benign vascular lesion characterized by a proliferation of blood-filled vascular spaces lined by a single layer of endothelial cells and separated by connective tissue septa of varying thickness. Some glomangiomas contain prominent large, dilated vascular spaces that appear similar to those of cavernous hemangiomas; however, cavernous hemangiomas lack the characteristics perivascular glomus cells of glomangioma. True cavernous hemangiomas are rare in the colon.

B. Arteriovenous malformation: Arteriovenous malformations are composed of dilated, irregular, and tortuous arteries and veins. They lack a population of perivascular glomus cells. Endoscopically, arteriovenous malformations tend to present as flat red-purple to blue vascular lesions, although they can also have a polypoid appearance.

D. Angioleiomyoma, cavernous type: Like glomangiomas, cavernous type angioleiomyomas are mesenchymal lesions characterized by prominent dilated vascular spaces and typically show strong, diffuse expression of SMA and positivity for calponin and h-caldesmon. Unlike glomangiomas, angioleiomyomas are composed of well-developed smooth muscle bundles that tend to be positive for desmin. Angioleiomyomas are most commonly found in the extremities and are exceedingly rare in the gastrointestinal tract.

E. Lymphangioma/lymphangiectasia: Lymphangiomas/lymphangiectasias are composed of dilated lymphatic channels lined by a single layer of bland, flattened endothelial cells that can be highlighted by D2-40 immunohistochemistry. They lack perivascular glomus cells. The dilated lymphatic spaces may contain proteinaceous material, lymphocytes, and/or erythrocytes - features

not typically seen in glomangiomas. Endoscopically, lymphangiectasia generally appears as swollen, white, granular mucosa, while lymphangioma tends to appear as a well-circumscribed polypoid or pedunculated lesion. Both occur more commonly in the small intestine than in the colon.

Discussion

Glomus tumors are rare pericytic mesenchymal neoplasms thought to derive from perivascular modified smooth muscle cells akin to those of the normal glomus body. They are typically composed of uniform cells with pale to clear, eosinophilic, or amphophilic cytoplasm and small, round, centrally located nuclei. In general, glomus tumors do not display significant mitotic activity or necrosis, and cytologic atypia is uncommon. Immunohistochemically, they are usually positive for SMA, muscle-specific actin (MSA), collagen type IV, h-caldesmon, and calponin. CD34 expression is typically absent or focal, while S100 and cytokeratin are generally negative. Solid glomus tumors, which account for 75% of cases, are usually well circumscribed and may have a fibrous pseudocapsule. Glomangioma is the second most common morphologic variant of glomus tumor (after solid type) and is distinguished by prominent, dilated vascular spaces surrounded by clusters of glomus cells. The vascular spaces may resemble those of cavernous hemangioma, and secondary thrombosis may be occasionally present. Glomangiomas are often less well-circumscribed compared with conventional solid glomus tumors.

Glomus tumors are most often found in the distal extremities, especially in subungual locations (e.g., nailbed), where they typically present as solitary, subcentimeter, painful red or blue nodules. Although rare outside the extremities, glomus tumors have been reported in nearly all anatomic sites. Within the gastrointestinal tract, they most commonly arise in the stomach but have also been documented in the esophagus, small intestine, and colon.[1, 2, 3] In the colon, only 6 cases have been reported. Of these, only 2 presented endoscopically as polyps, and none of the reported cases demonstrated the histologic features of glomangioma. To our knowledge, the present case therefore represents the first reported case of colonic glomangioma.

Glomus tumors are generally seen in adults between 20 and 40 years of age and have been reported across a wide age range. Gastrointestinal glomus tumors tend to occur in older adults.[3] The majority of glomus tumors are benign, with complete surgical excision being curative in most cases. A 10% recurrence rate is thought to be related to incomplete resection.[4] Malignant glomus tumors are uncommon but clinically aggressive. The rarity of malignant glomus tumors, and in particular malignant gastrointestinal glomus tumors, serves as a limitation for defining malignancy. However, in the stomach and gastroesophageal junction, the following features have been

associated with development of metastasis: (1) size ≥ 5 cm, and/or (2) cytologic atypia (i.e., spindle cell morphology, nuclear enlargement, irregularity, pleomorphism, or coarse chromatin) plus mitotic activity ≥2 mitoses per 10 high-power fields.[3, 5, 6, 7] This is somewhat similar to the proposed criteria for glomus tumors of all sites: deep location and size > 20 mm, or atypical mitotic figures, or moderate to high nuclear grade and ≥ 5 mitoses/10 mm2. A subset of tumors show some, but not all, features associated with malignancy and may be considered to be of uncertain malignant potential.[5]

The most frequent molecular alterations in glomus tumors are *NOTCH* rearrangements, which have been identified in both benign and malignant tumors. In one study, *NOTCH2* rearrangements were detected in all 5 malignant glomus tumors analyzed.[8] *BRAF* and *KRAS* mutations have also been reported in sporadic glomus tumors. Of note, one study identified the *BRAF* p.Val600Glu (V600E) mutation exclusively in tumors classified as malignant or of uncertain malignant potential.[9] Therefore, the presence of the *BRAF* V600E mutation may be associated with more aggressive behavior and could represent a potential therapeutic target in advanced or unresectable disease.[10] Another study reported that all tumors with malignant histological/clinical features showed complex copy-number alterations, including *ATRX* inactivation and recurrent loss of 9p21.3 (*CDKN2A/B* and *MTAP*).[7]

Despite most glomus tumors presenting as solitary lesions, approximately 10% of patients have multiple lesions. Familial glomus tumors are associated with the development of multiple glomus tumors, and result from loss-of-function mutations in *GLMN*, which encodes glomulin, a protein predominantly expressed in vascular smooth muscle cells. Neurofibromatosis type 1 associated glomus tumors have also been reported and are related to biallelic *NF1* inactivation.

In summary, glomus tumors are typically benign mesenchymal neoplasms that rarely arise in the gastrointestinal tract. In the present case of colonic glomangioma, the lesion's location in the deep submucosa makes it relatively inconspicuous, and it may be overlooked on initial examination. Once identified, its histologic appearance raises a differential diagnosis of many vascular lesions, including cavernous hemangioma, angioleiomyoma, arteriovenous malformation, and lymphangioma/lymphangiectasia. Recognition of the characteristic perivascular glomus cell component is essential for accurate classification. Immunohistochemistry can confirm the smooth muscle/pericytic phenotype of the lesional cells and exclude alternative lines of differentiation, thereby supporting the correct diagnosis.

References

1. Chen IY, Fazili BG, Liao X. Glomus Tumor of the Colon: A Rare Case Report and Review of Literature. *International Journal of Surgical Pathology*. 2020;28(6):691-695.

2. Chen G, Wang M, Lin Y, Lin X. Indeterminate malignant potential glomus tumor of the esophagus: A case report. *Medicine*. 2025;104(22):e42049.

3. Miettinen M, Paal E, Lasota J, Sobin LH. Gastrointestinal glomus tumors: a clinicopathologic, immunohistochemical, and molecular genetic study of 32 cases. *American Journal of Surgical Pathology*. 2002;26(3):301-311.

4. Gombos Z, Zhang PJ. Glomus tumor. *Archives of Pathology & Laboratory Medicine*. 2008;132(9):1448-1452.

5. WHO Classification of Tumours Editorial Board. Glomus tumour. In: *Digestive System Tumours*. 6th ed. Lyon, France: International Agency for Research on Cancer; 2026. WHO Classification of Tumours Series, Vol 1.

6. Folpe AL, Fanburg-Smith JC, Miettinen M, Weiss SW. Atypical and malignant glomus tumors: analysis of 52 cases, with a proposal for the reclassification of glomus tumors. *American Journal of Surgical Pathology*. 2001;25(1):1-12.

7. Papke DJ Jr, Sholl LM, Doyle LA, Fletcher CDM, Hornick JL. Gastroesophageal Glomus Tumors: Clinicopathologic and Molecular Genetic Analysis of 26 Cases With a Proposal for Malignancy Criteria. *American Journal of Surgical Pathology.* 2022;46(10):1436-1446.

8. Mosquera JM, Sboner A, Zhang L, Chen CL, Sung YS, Chen HW, Agaram NP, Briskin D, Basha BM, Singer S, Rubin MA, Tuschl T, Antonescu CR. Novel MIR143-NOTCH fusions in benign and malignant glomus tumors. *Genes, Chromosomes and Cancer*. 2013;52(11):1075-1087.

9. Karamzadeh Dashti N, Bahrami A, Lee SJ, Jenkins SM, Rodriguez FJ, Folpe AL, Boland JM. BRAF V600E Mutations Occur in a Subset of Glomus Tumors, and Are Associated with Malignant Histologic Characteristics. *American Journal of Surgical Pathology*. 2017;41(11):1532-1541.

10. Cuviello A, Goyal A, Zick A, Ahlawat S, Rodriguez FJ, Belzberg AJ, Pratilas CA. Sporadic Malignant Glomus Tumor of the Brachial Plexus With Response to Targeted Therapy Directed Against Oncogenic *BRAF*. *JCO Precision Oncology*. 2018;2:1-7.

Author information

Ellika Salari, MD (GI/Liver Pathology Fellow, UC Davis Health)

Karen Matsukuma, MD, PhD (Director, GI/Liver Pathology Fellowship, UC Davis Health)